



OPEN ACCESS

EXTENDED REPORT

Assessment of disease activity in patients with rheumatoid arthritis using optical spectral transmission measurements, a non-invasive imaging technique

M van Onna,¹ D F Ten Cate,² K L Tsoi,³ A J L Meier,⁴ J W G Jacobs,³
A A A Westgeest,⁴ P B L Meijer,⁵ M C van Beek,⁵ W H J Rensen,⁵ J W J Bijlsma³

Handling editor Tore K Kvien

► Additional material is published online only. To view please visit the journal online (<http://dx.doi.org/10.1136/annrheumdis-2015-207315>).

For numbered affiliations see end of article.

Correspondence to

Dr M van Onna, Department of Clinical Immunology and Rheumatology, Academic Medical Center, F4-105, PO Box 2260, Amsterdam 1100 DD, The Netherlands; m.vanonna@amc.uva.nl

Received 20 January 2015

Revised 9 September 2015

Accepted 20 September 2015

Published Online First

9 October 2015



Open Access
Scan to access more
free content



CrossMark



- <http://dx.doi.org/10.1136/annrheumdis-2015-207345>
- <http://dx.doi.org/10.1136/annrheumdis-2015-208399>
- <http://dx.doi.org/10.1136/annrheumdis-2015-208661>

To cite: van Onna M, Ten Cate DF, Tsoi KL, et al. *Ann Rheum Dis* 2016;**75**: 511–518.

ABSTRACT

Objectives In rheumatoid arthritis (RA), treat-to-target strategies require instruments for valid detection of joint inflammation. Therefore, imaging modalities are increasingly used in clinical practice. Optical spectral transmission (OST) measurements are non-invasive and fast and may therefore have benefits over existing imaging modalities. We tested whether OST could measure disease activity validly in patients with RA.

Methods In 59 patients with RA and 10 patients with arthralgia, OST, joint counts, Disease Activity Score (DAS) 28 and ultrasonography (US) were performed. Additionally, MRI was performed in patients with DAS28<2.6. We developed and validated within the same cohort an algorithm for detection of joint inflammation by OST with US as reference.

Results At the joint level, OST and US performed similarly in proximal interphalangeal-joints (area under the receiver-operating curve (AUC) of 0.79, $p<0.0001$) and metacarpophalangeal joints (AUC 0.78, $p<0.0001$). Performance was less similar in wrists (AUC 0.62, $p=0.006$). On the patient level, OST correlated moderately with clinical examination (DAS28 $r=0.42$, $p=0.001$), and US scores ($r=0.64$, $p<0.0001$). Furthermore, in patients with subclinical and low disease activity, there was a correlation between OST and MRI synovitis score (RAMRIS (Rheumatoid Arthritis MRI Scoring) synovitis), $r=0.52$, $p=0.005$.

Conclusions In this pilot study, OST performed moderately in the detection of joint inflammation in patients with RA. Further studies are needed to determine the diagnostic performance in a new cohort of patients with RA.

INTRODUCTION

The prognosis of rheumatoid arthritis (RA) has greatly improved with treatment targeting at remission.¹ This requires instruments for valid detection of disease activity. Generally, the 28-joint Disease Activity Score (DAS28) is used for this. However, DAS28 has not been validated for use in individual patients, has considerable test–retest variability^{2 3} and is also influenced by several factors unrelated to joint inflammation.^{4 5} Imaging techniques such as ultrasonography (US) and MRI are more sensitive for the detection of synovitis than physical assessment,⁶ but they are not applied as standard assessments yet.⁷ There is an unmet need for

objective, fast measurement of disease activity at low cost, applicable during outpatient visits.

Optical spectral transmission (OST) measures the transmission of light of specific wavelengths quantitatively. The same technique is used in pulse oximetry.⁸ In the presence of synovitis, the transmission of light decreases,^{9 10} which is due to vascular changes.¹¹ There is one commercially available optical device which measures reflection of light on illumination, before and after intravenously administered indocyanine green (fluorescence optical imaging (FOI)).^{12 13} OST measures the transmission of light before and after temporarily impeding the venous return of blood from the forearms. Using this approach, OST through a single joint (proximal interphalangeal (PIP)) has shown to correlate with the detection of synovitis by physical examination.¹⁴ A multijoint OST device (Full Hand Prototype (FHP)) has been developed, which was used in our current study. In this pilot study, we tested whether the FHP could measure disease activity accurately in patients with RA.

METHODS

Subjects

Fifty-nine patients with RA and 10 controls with non-inflammatory arthralgia of unknown cause were recruited at the outpatient clinics of the departments of rheumatology at the University Medical Center Utrecht (UMCU) and Regional Rheumatology Center Eindhoven between November 2011 and June 2012. The aim was to include 20 patients for each category of disease activity, DAS28<2.6, $2.6\leq\text{DAS28}\leq 5.1$, DAS28>5.1. Preliminary stratification during recruitment was based on the DAS28 at the time of the screening visit at the outpatient clinic. Final stratification was based on the DAS28 measured at the day of examination, which resulted in 20 patients with DAS28<2.6, 26 with $2.6\leq\text{DAS28}\leq 5.1$ and 13 with DAS28>5.1. Time between recruitment and enrolment was less than 3 weeks. In all subjects clinical assessments, US and OST were performed. In order to be clinically useful, an imaging technique should be able to measure subclinical disease activity. To examine this in more detail, we performed in patients with DAS28<2.6 at recruitment, not only US but also MRI. Exclusion criteria were age less than 18 or over 90 years, significant deformities of the hand, wheelchair dependency, surgery of the

Table 1 Patient demographics and clinical data

	Arthralgia	Rheumatoid arthritis		
		DAS28<2.6	2.6≥DAS28≤5.1	DAS28>5.1
Patients (number)	10	20	26	13
Age (year)	39±8	48±15	59±8	57±12
Female (%)	100	70	58	54
Duration of arthralgia (year)	3 (1–15)	–	–	–
Duration of RA (year)	–	3 (2–4)	9 (3–17)	1 (0–6)
ACPA positivity (%)	0	65	77	69
DAS28	3.2±0.9	1.7±0.4	3.8±0.8	5.9±0.6
ESR (mm 1st hour)	9 (5–13)	6 (3–10)	14 (8–24)	37 (21–55)
Raynaud's phenomenon (%)	0	0	11	15
Use of β-blockers (%)	0	5	23	0
Use of calcium channel blockers (%)	0	15	0	0

Numbers are presented as mean±SD or median (IQR) unless mentioned otherwise.

Mean of the two physical examiners. Examined joints: shoulders, elbows, wrists, MCP and (P)IP joints of hands and knees.

ACPA, anti-citrullinated protein antibody; DAS, Disease Activity Score; ESR, erythrocyte sedimentation rate; MCP, metacarpophalangeal; RA, rheumatoid arthritis.

wrist or hand in the preceding 3 months, light hypersensitivity, pregnancy and/or breastfeeding. In the MRI subgroup only, additional exclusion criteria were applied: allergy to gadolinium, presence of MRI-incompatible metal objects in any part of the body, renal insufficiency (defined as Modification of Diet in Renal Disease (MDRD) <30 mL/min/1.73 m²) and/or claustrophobia. All measurements were performed within a window of 4 h at the University Medical Center Utrecht. The study complied with the Declaration of Helsinki. The study protocol was approved by the ethics committees of the UMCU and Maxima Medical Center

Eindhoven. All study participants gave written informed consent prior to study inclusion.

Clinical assessment

Comorbidities, current drug use, presence of Raynaud's phenomenon and the presence of visible wounds on hands or wrists were recorded. Subjects filled out a global assessment of disease activity on a Visual Analogue Scale (0–100). A swollen and tender joint count was performed by a physician (KLT) and a research nurse (AJLM) in all subjects, in random order.

Table 2 Involvement of wrists, MCP and PIP joints

		Rheumatoid arthritis		
	Arthralgia	DAS28<2.6	2.6≥DAS28≤5.1	DAS28>5.1
No. of affected joints				
Tender joints (0–22)*	1 (0–4)	0 (0–1)	2 (1–6)	11 (5–13)
Swollen joints (0–22)*	0 (0–0)	0 (0–1)	2 (1–4)	6 (4–9)
GSUS>1 (0–22)	0 (0–0)	0 (0–0)	1 (0–2)	2 (1–5)
PDUS>0 (0–22)	0 (0–0)	0 (0–1)	1 (0–4)	2 (1–6)
US synovitis (GSUS>1 and/or PDUS>0) (0–22)	0 (0–0)	0 (0–1)	1 (0–4)	2 (1–6)
GSUS tenosynovitis (0–22)	0 (0–0)	0 (0–0)	0 (0–0)	0 (0–1)
PDUS tenosynovitis (0–22)	0 (0–0)	0 (0–1)	0 (0–2)	1 (0–5)
US inflammation (GSUS>1 and/or PDUS>0 and/or PDUS tenosynovitis) (0–22)	0 (0–0)	1 (0–2)	2 (0–5)	3 (2–7)
MRI joint count (synovitis>0) (0–6)†	–	5 (3–5)	4 (4–5)	–
MRI joint count (bone marrow oedema) (0–6)†	–	1 (0–1)	1 (0–1)	–
Severity of affected joints				
GSUS joint index (synovitis+tenosynovitis) (0–88)	1 (0–1)	2 (1–3)	5 (2–7)	9 (2–13)
PDUS joint index (synovitis+tenosynovitis) (0–88)	0 (0–0)	0 (0–2)	2 (0–7)	5 (2–12)
US joint index (GSUS synovitis+GSUS tenosynovitis+PDUS synovitis+PDUS tenosynovitis) (0–176)	1 (0–1)	2 (1–4)	6 (3–1)	13 (4–27)
RAMRIS synovitis (0–21)	–	6 (4–8)	6 (4–7)	–
RAMRIS bone marrow oedema (0–69)	–	1 (0–2)	1 (0–2)	–
RAMRIS (0–320)	–	13 (8–18)	19 (10–23)	–
OST joint index‡	4.13 (3.42–5.49)	4.40 (3.48–5.10)	5.90 (4.37–7.49)	7.35 (4.27–10.28)

Number of affected joints are presented as median (IQR).

*Average of the two physical examiners.

†MCP 1–5 and radiocarpal and intracarpal joints on right side only. MRI was performed in patients with DAS28<2.6 at recruitment; all patients with DAS28<2.6 at the study day and additionally 7 patients with 2.6≥DAS28≤5.1 (median (IQR) DAS28 of these 7 patients was 3.2 (2.9–3.3)).

‡Kruskal–Wallis one-way analysis of variance p=0.001.

DAS, Disease Activity Score; GSUS, grey-scale US; MCP, metacarpophalangeal; OST, optical spectral transmission; PDUS, power Doppler US; PIP, proximal interphalangeal; RAMRIS, Rheumatoid Arthritis MRI Scoring; US, ultrasonography.

The examiners were blinded to the result of each other's assessments and other study measurements. The kappa for inter-rater agreement for tender joints was 0.50 and for swollen joints 0.52.

Ultrasonography

US was performed by one experienced examiner (DFTC (physician)) who was blinded to the results of other study measurements. A MyLab 60 system (Esaote, Genua, Italy) with an 18-6 MHz linear array transducer was used. Grey-scale US (GSUS) was performed of metacarpophalangeal (MCP) 1–5 (dorsal side), (PIP) 1–5 of hands (volar side), radiocarpal and mid-carpal joints (dorsal side) and flexor and extensor tendons of fingers and wrists. Patient and probe positioning were according to EULAR guidelines.¹⁵ Synovitis on GSUS and power Doppler US (PDUS) was classified using Outcome Measurements in Rheumatology Clinical Trials (OMERACT) definitions of ultrasonographic joint pathology and graded semi-quantitatively according to a modification of Szkudlarek's grading system,¹⁶ combining the criteria for joint effusion and synovial thickening. PDUS was performed only if the GSUS synovitis score was greater than 0. This study was designed well before the introduction of the OMERACT scoring system for tenosynovitis.¹⁷ At the time, no generally accepted criteria were available and the range of reference values for hypoechoic or anechoic rims around a tendon is very broad. Therefore, we chose to define GSUS tenosynovitis as a hypoechoic or anechoic rim around a tendon exceeding 2 mm.¹⁸ This was registered as being absent or present. PDUS of tendons was performed in case of (any) hypoechoic or anechoic thickened tissue with or without fluid within the tendon sheath seen in two perpendicular planes. This was registered as being absent or present.

Grade 1 GSUS synovitis has also been found in healthy subjects^{18–19} and is of limited prognostic value in RA.^{19–20} Therefore, US inflammation was defined as (GSUS synovitis >1 and/or PDUS synovitis >0 and/or GSUS/PDUS tenosynovitis >0). For individual subjects, the number of joints with inflammation was counted (US joint count). Also, the sum of GSUS synovitis, GSUS tenosynovitis, PDUS synovitis and PDUS tenosynovitis scores were calculated (US joint index).

MRI

Imaging was performed on a 1.5 Tesla MRI. (Philips Ingenia 1.5T, Philips Healthcare, Eindhoven, The Netherlands). The following sequences were acquired: Coronal T1-weighted turbo spin-echo images (TR/TE, 450/7.2; matrix size, 328×159; field of view, 18 cm; slice thickness, 2.5 mm), transversal T1-weighted turbo spin-echo images (TR/TE, 500/12; matrix size, 300×185; field of view, 12 cm; slice thickness, 2.5 mm), Coronal T2-weighted short-tau inversion recovery images (TR/TE, 3251/150; inversion time, 150; matrix size, 328×140; field of view, 18 cm; slice thickness, 2.5 mm). T1 images were acquired before and after intravenous gadolinium contrast administration. Images were scored by one experienced MRI reader and rheumatologist according to OMERACT Rheumatoid Arthritis MRI Scoring (RAMRIS) method, evaluating synovitis in MCP2-5 and the wrists. The reader was blinded to the results of other study measurements. The same image set was scored twice with at least a 2-week interval; results were averaged. The kappa for intrarater agreement was 0.25; if joints with synovitis grade 1 were excluded, kappa was 0.80. Similar to US, the number of joints with synovitis was counted (MRI joint count).

Optical transmission measurements

OST measurements were performed with the FHP in a standardised way operated by a rheumatology nurse (AJLM). Both hands were inserted through cylindrical openings that contained pressure cuffs. light-emitting diode (LED) lights (wavelengths of 660 and 810 nm) illuminated the (PIP) MCP and wrist joints of both hands and reference areas from the palmar side. Light transmitted through the joints and reference areas was recorded continuously at the dorsal side by charge-coupled device (CCD) camera with a frame rate of at least six per second, alternatingly

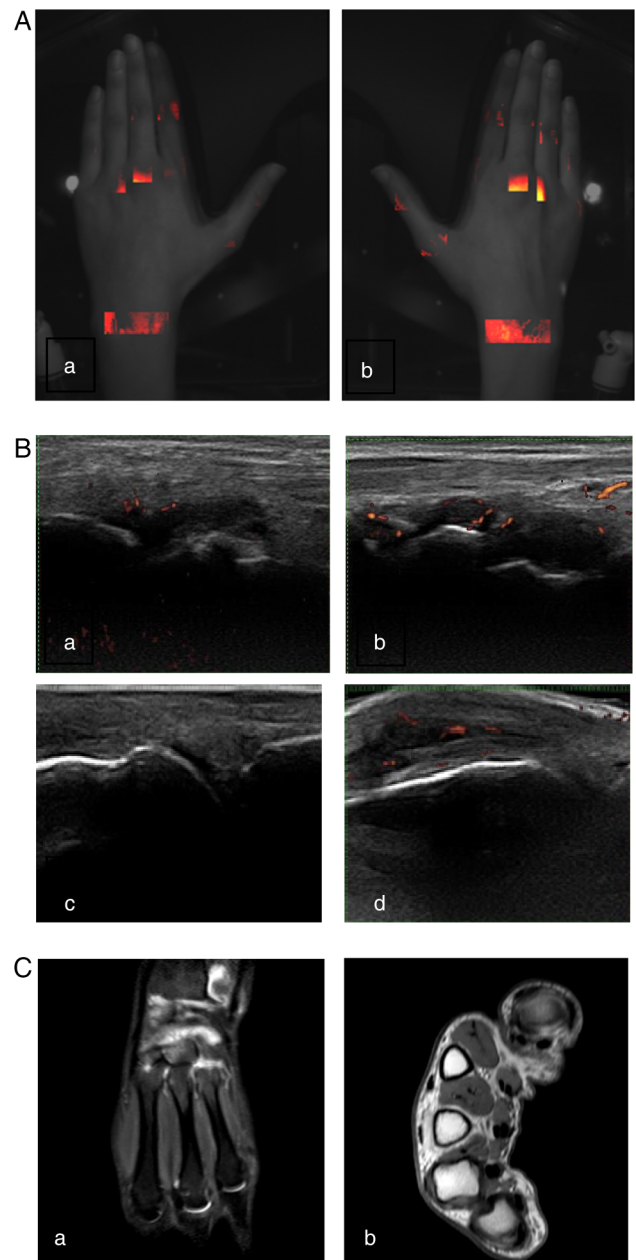


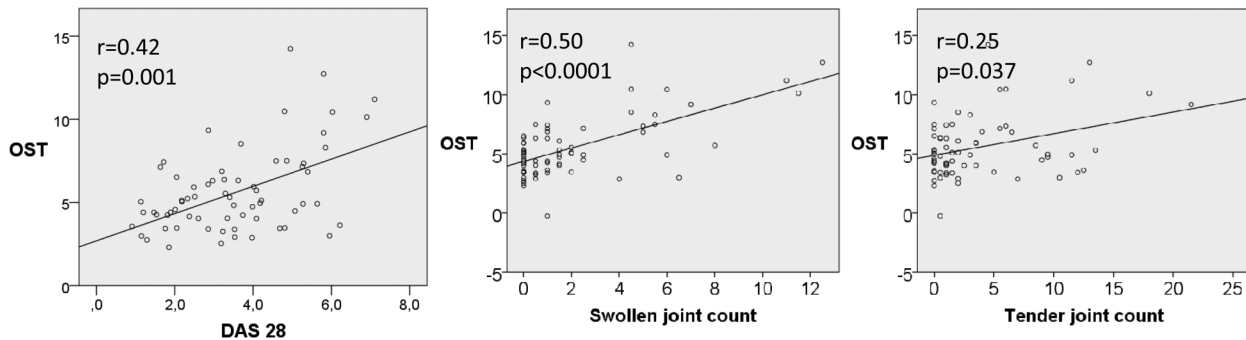
Figure 1 Subclinical inflammation in a patient with rheumatoid arthritis in clinical remission. Representative images of a patient without clinically detectable arthritis. All imaging techniques show synovitis of both wrists and metacarpophalangeal (MCP)3 of the right hand. Both hands with (A) Full Hand Proto, (B) grey-scale and power Doppler ultrasonography of joints of left (a) and right wrist (b) and left and right MCP3 (c and d) (C) MRI of right wrist T2 short-tau inversion recovery (STIR) (a) and MCP joints of the right MCP (b, T1 with gadolinium enhancement).

for the 660 nm wavelength, the 810 nm wavelength and without illumination (background image). A complete measurement was performed within 90 s: first, inflation of the cuff to 5 mm Hg (15 s); second, inflation of the cuff to 50 mm Hg (60 s) and finally deflation of the cuff (15 s).

Image analysis was performed by PBLM using in-house developed software (InFlame RA-120159, December 10, 2012), blinded to the results of other study measurements. Regions of interest (ROI) were traced manually for all joints (joint ROI)

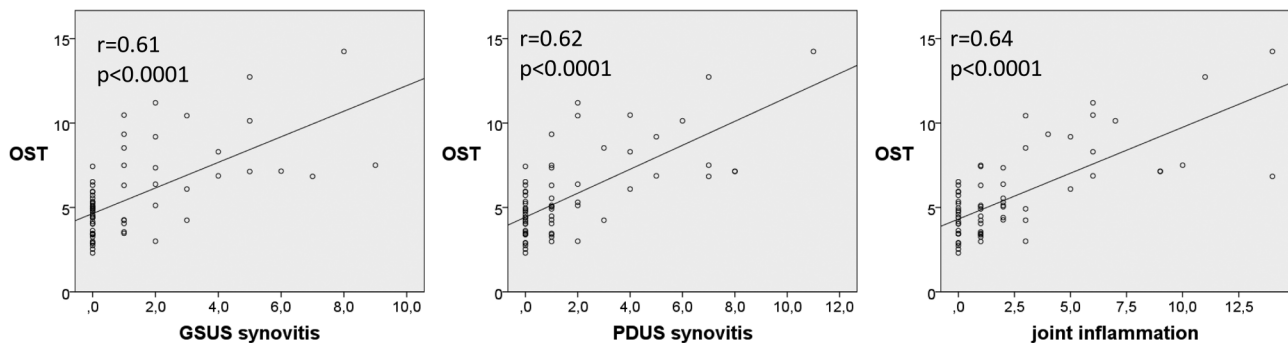
and automatically for a position distal to each joint (reference ROI) based on the pictures taken by the CCD camera. Landmarks for joint ROI were broadening of the phalanx and wrinkles of the skin for (P)IP-joints, web between the fingers for MCP joints and curvatures of distal radius and ulna. An ROI consisted of approximately 100 pixels. The recorded intensity of each pixel in a ROI versus the measurement time was fitted to a curve representing the response to inflation and deflation of the pressure cuff, separately for the 660 nm and the 810 nm

A OST versus clinical examination



B OST versus ultrasonography

B1: joint count



B2. Joint index

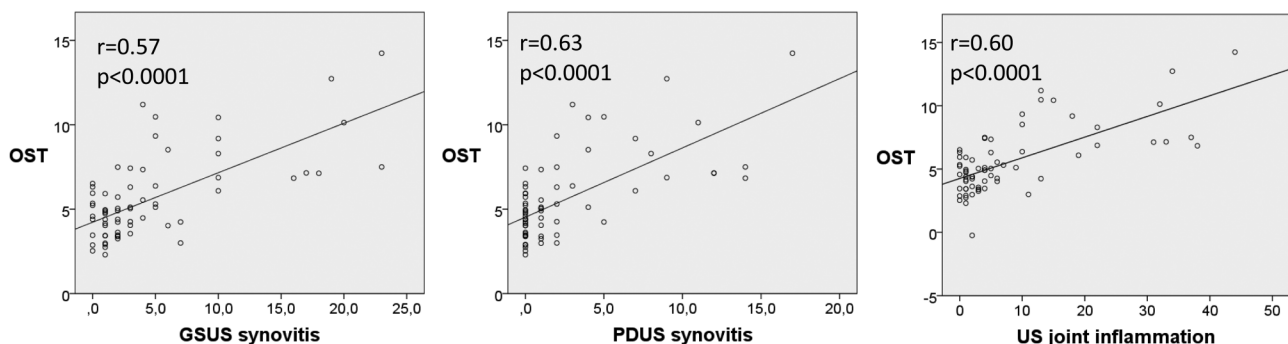


Figure 2 Patient level: relationship between optical spectral transmission (OST) and clinical examination, ultrasonography (US) and MRI. (A) Correlation between OST and clinical examination (DAS28, swollen joint count of 28 joints and tender joint count of 28 joints). (B) Correlation between OST and US, upper three panels with count of number of joints with grey-scale US (GSUS) synovitis (left panel), count of number of joints with power Doppler US (PDUS) synovitis (middle panel) and count of joints with inflammation with US (right panel). US inflammation was defined as (GSUS synovitis >1 or PDUS synovitis >0 and/or GSUS/PDUS tenosynovitis >0). Lower three panels show correlation of OST with joint indexes (sum of semi-quantitative US scores) of GSUS synovitis (left panel), PDUS synovitis (middle panel) and US inflammation (right panel). (C) Correlation between OST and MRI. Rheumatoid Arthritis MRI Scoring (RAMRIS) (left panel) and its components (RAMRIS synovitis (middle panel) and RAMRIS bone marrow oedema (right panel)).

C OST versus MRI

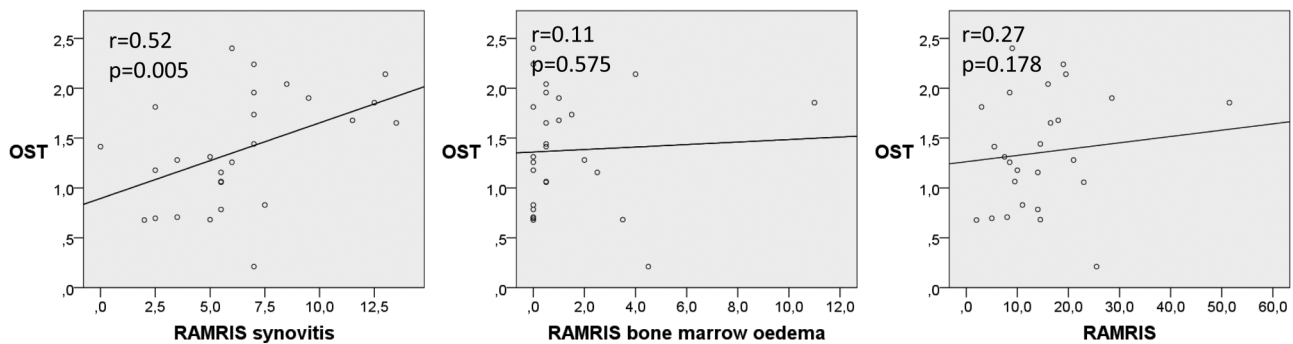


Figure 2 (Continued).

wavelength (the optical transmission response curve, see online supplementary figure S1). The optical response curve of a pixel could be described by eight curve parameters per wavelength, that is, 16 curve parameters for both wavelengths combined. The average of a curve parameter over pixels in an ROI was calculated, giving 16 parameters per ROI. Reference ROIs allowed for correction for systemic effects unrelated to inflammation, such as body temperature and the use of vasoactive medication. This was done by subtracting reference ROI parameters from joint ROI parameters and then dividing this difference by the average of reference ROI parameters and joint ROI parameters. Thus, image analysis yielded 16 normalised parameters per joint for use in regression analyses.

Statistical analysis

We developed and internally validated an algorithm for detection of joint inflammation by OST with US as reference by multiple regression analysis. Data of all patients were used in the development and internal validation. The dependent variable was defined as the maximum of GSUS and PDUS scores for synovitis and tenosynovitis (range 0–3), and the normalised joint parameters as independent variables. A stepwise forward selection procedure with adjusted R^2 testing was used to determine which variable to add. This was repeated until either R^2 no longer increased (cut-off value of 0) or, to prevent overfitting of the model, a maximum of four parameters had been selected. This was done separately for each joint region, so separately for (P)IP, MCP and wrists. We tested whether individual observations exerting undue influence on the coefficients in the regression analysis (outliers) were present and if so they were removed from the development phase. The regression analysis with the four parameters as independent variables per joint region was then performed using leave-one-out cross validation to detect and prevent overfitting. In this analysis, the model is repeatedly refit, leaving out at each fit a different, single patient. The regression coefficients thus obtained are used to calculate OST values for the left-out observation. For individual subjects, an OST joint index over all joints ((P)IP 1–5, MCP 1–5 and wrists of both hands) was calculated. The diagnostic performance of OST was compared with clinical examination, DAS28, US and MRI by receiver operating curve analyses with 95% CI estimation, separately at the patient level (one score per patient) and individual joint level (one score per joint). Presence (yes/no) of (teno)synovitis on US was used as reference. Correlations were calculated using Spearman's rank correlation coefficient. Differences between group medians were tested for significance using either the Mann–Whitney U test for two groups or the

Kruskal–Wallis one-way analysis of variance for three or more groups. p Values below 0.05 (two-sided tests) were considered to be statistically significant. Inter- and intrarater agreement was calculated by the kappa statistic. The multiple regression analyses were performed using Hemics in-house software (InFlame RA-120159), all other analyses by SPSS version 21.

RESULTS

Subjects

Demographic and clinical data are reported in table 1. Table 2 depicts the number and severity of affected PIP, MCP and wrist joints per patient with clinical examinations, US and OST.

Optical transmission

All subjects tolerated the OST measurements well; no adverse events or side effects were observed. Figure 1 depicts an example of the results of OST, US and MRI in a patient in

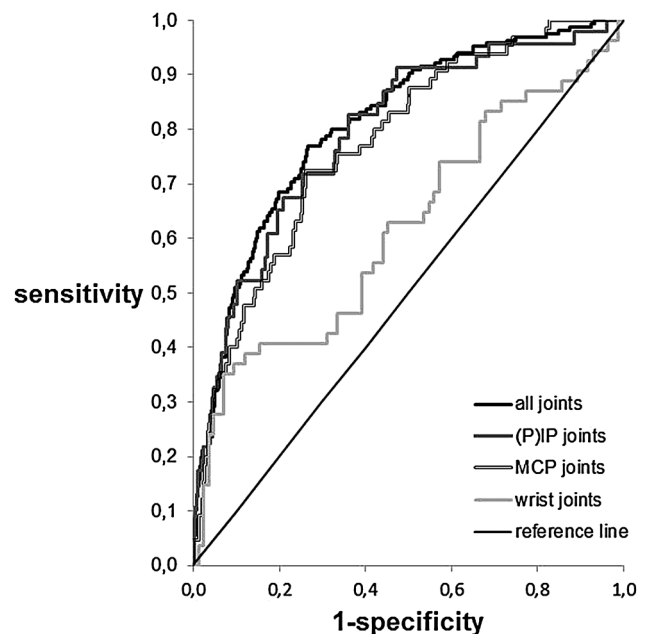


Figure 3 Area under the curve (AUC) between optical spectral transmission (OST) and ultrasonography (US) at the joint level. Area under ROC of the OST in all joints (AUC 0.81, 0.77 to 0.84, $p<0.0001$), (P)IP joints (AUC 0.79, 0.72 to 0.86, $p<0.0001$), metacarpophalangeal (MCP) joints (AUC 0.78, 0.71 to 0.83, $p<0.0001$) and wrists (0.62, 0.52 to 0.72, $p=0.018$) (US as reference).

clinical and DAS28 remission. One patient was identified as an outlier. We looked into reasons for this, such as presence of Raynaud's phenomenon or use of vasoactive drugs. We could not identify an explanation. This patient was therefore left out of the analyses for the development of the algorithm, but not of the validation. This was a patient with many active joints. The OST scores of the subjects with Raynaud's phenomenon and/or using drugs that may alter peripheral blood flow were not outliers.

Comparison of OST with clinical examination, US and MRI

Median OST was different between the four groups ($p=0.001$). The correlation coefficients between OST and US were higher than those between OST and clinical examination (figure 2). The correlation coefficients between OST and MRI and OST and clinical examination were about similar; however, they are difficult to compare since MRI was only performed in patients with remission or low disease activity and restricted to wrist and MCP joints of one hand.

Joint level: comparison of OST scores with those at US

Diagnostic performance of OST was tested with inflammation as detected by US as reference standard (figure 3). Overall, OST had a good performance (AUC 0.81, 95% CI 0.77 to 0.84). When testing separately for the (P)IP, MCP and wrists joints, the OST of the (P)IP and MCP joints showed a good discrimination (AUC of 0.79, 95% CI 0.72 to 0.86, $p<0.0001$ and 0.78, 95% CI 0.71 to 0.83, $p<0.0001$, respectively). For the wrists it was poor (AUC 0.62, 95% CI 0.52 to 0.74, $p=0.006$). Since OST generates quantitative results, values for sensitivity and specificity of OST depend on the chosen cut-off value (figure 3). The values for inflammation as defined by OST with maximum sensitivity and specificity were 0.11 for the (P)IP joints (sensitivity of 83%, specificity of 64%), 0.26 for the MCP joints (sensitivity of 70%, specificity of 74%) and 1.0 for the wrists (sensitivity of 39%, specificity of 87%). In comparison, the test characteristics

of clinical examination (of the two examiners combined) of swollen joints were sensitivity 59%, specificity 86% for the PIP joints, a sensitivity 42% and a specificity of 93% for the MCP joints and a sensitivity 37% and specificity of 89% for the wrists (figure 4).

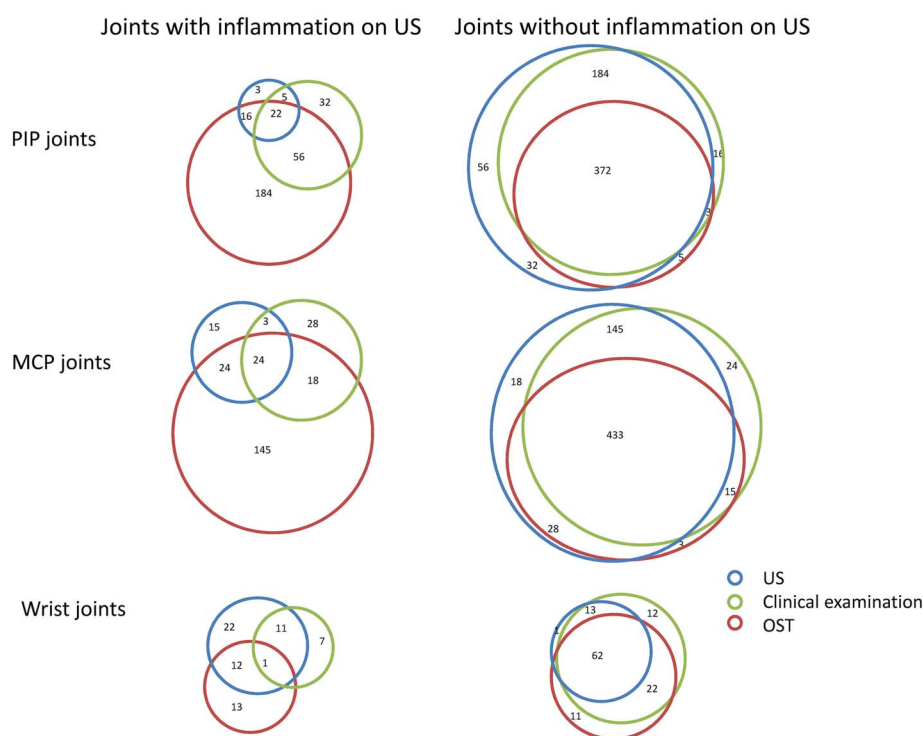
DISCUSSION

In this study, we found that OST measurements agreed moderately with clinical assessments, US and MRI. The level of agreement was highest with items (directly) reflecting synovial vascularity, such as PDUS. As light does not penetrate through bone, we found no agreement between OST and MRI bone marrow oedema. Diagnostic performance of OST was better in small hand joints (MCP and (P)IP joints) than in the wrists. The sensitivity (but not specificity) of detection of synovitis was higher than that of clinical examination for (P)IP (83% vs 59%) and MCP joints (70% vs 42%); it was similar for the wrists (39% vs 37%). The sensitivity and specificity are, however, lower than those for US and MRI,⁶ but regular use of these techniques is not feasible in most clinics. Our pilot study shows an increased detection rate which may be clinically relevant, provided that the results are replicated in new cohorts.

Studies on FOI, an invasive technique using light to detect inflammation, have been published earlier.^{12 13 21–23} It seems that in FOI as well as in OST, the diagnostic performance is inversely related to the size of the joint. The differences in design (such as investigated joints areas, diagnosis) and technique used in the FOI studies hamper the full comparison of these results with our own. However, our study shows at least equivalent, or even slightly higher, sensitivity and specificity at detecting synovitis at the joint level, than the commercially available device for FOI. Additional advantages of our technique are its non-invasiveness and the generation of quantitative results ruling out interobserver variability.

This study has some limitations. There was a risk of model overfitting because US was used both as reference standard in

Figure 4 Example of diagnostic performance of optical spectral transmission (OST) versus ultrasonography (US) and clinical examination at a chosen cut-off. Since OST generates quantitative results, values for sensitivity and specificity of OST depend on the chosen cut-off value. The values for inflammation as defined by OST with maximum sensitivity and specificity were 0.26 for the metacarpophalangeal (MCP) joints (sensitivity of 70%, specificity of 74%), 0.11 for the proximal interphalangeal ((P)IP) joints (sensitivity of 83%, specificity of 64%) and 1.0 for the wrists (sensitivity of 39%, specificity of 87%). This figure shows the number of correctly classified joints with and without inflammation (US as reference) by OST (using the above-mentioned cut-off values) as the overlapping parts of the red and the blue circles per joint type. Similarly, the number of correctly classified joints by clinical examination (swollen joints) are shown as the overlapping parts of the blue and the green circles. Numbers denote the number of patients in a category.



the development of the algorithm and in the evaluation of diagnostic performance. We have tried to reduce overfitting by using a relatively large development sample and leave-one-out cross validation. We think this strategy was successful because we also found a correlation between OST and MRI synovitis and MRI was not used in development of the algorithm. However, validation in a new cohort is still mandatory, especially since relatively few patients with severe synovitis were present in our study.^{24 25} Another possible limitation is that we used subjects with arthralgia as controls. In clinical practice, one wants to differentiate between arthritis and arthralgia. However, it is well known that in a subgroup of subjects, arthralgia may evolve in inflammatory arthritis and subclinical inflammation may already be present.²⁶ None of the subjects in our study developed inflammatory arthritis (>1 year after study completion). The diagnostic performance of OST in the wrists was rather poor, which may be related to the limited tissue penetration of light through larger structures. In addition, there was a low number of subjects with GSUS tenosynovitis. This may have been related to the rather strict definition. Low-grade PDUS negative tenosynovitis may have been missed. Further, US and OST were performed each by a single examiner (DFTC and AJLM, respectively). Therefore, interobserver variability could not be calculated. Intraobserver agreement for MRI was low; the agreement was good if joints with low-grade synovitis (grade 1) were excluded. Further, it has been shown that the interobserver reliability of US of the wrists is only moderate,^{27 28} which may be related to the (more) complex anatomy of the wrist in comparison with PIP and MCP joints. It is subject of further studies whether technical adjustments leading to more light penetration through the wrists are able to improve the accuracy of OST measurements of the wrists. Also, in the adjusted FHP, image analysis will be automated; OST will then be an operator-independent technique. Finally, and similar to other imaging techniques, before OST can be used to monitor patients with RA, its sensitivity to change should be investigated. New studies to evaluate diagnostic performance and sensitivity to change in a new cohort of patients with RA are planned.

In conclusion, OST is a new imaging technique that generates fast and quantitative results. In this pilot study, OST performed moderately in the detection of joint inflammation in patients with RA. Further studies are needed to determine the diagnostic performance in a new cohort of patients with RA.

Author affiliations

¹Department of Clinical Immunology and Rheumatology, Academic Medical Center, Amsterdam, The Netherlands

²Department of Rheumatology, Erasmus University Medical Center, Rotterdam, The Netherlands

³Department of Rheumatology and Clinical Immunology, University Medical Center Utrecht, Utrecht, The Netherlands

⁴Department of Rheumatology, Regional Rheumatology Center, Eindhoven, The Netherlands

⁵Hemics, Eindhoven, The Netherlands

Acknowledgements We thank Professor Dr P Conaghan for scoring the MRI's.

Contributors MvO, JWJG, AAW, MCvB, WHJR and JWJB conceived and designed the study. DFTC, KLT, AJLM and AAW acquired the data. MvO, JWJG and PBLM analysed the data. MvO, DFTC, JWJG and JWJB interpreted the results. MvO drafted the manuscript. All authors revised, critically commented and approved the final version of the manuscript.

Funding Hemics, Eindhoven, The Netherlands.

Competing interests MCvB and WHJR are cofounders of Hemics. PBLM, MCvB and WHJR own stock in the company. Hemics has filed a patent application for the optical spectral transmission imaging technology. JWJB received a Research Grant from Hemics.

Patient consent Obtained.

Ethics approval The study protocol was approved by the Ethics Committees of the UMCU and Maxima Medical Center Eindhoven. All study participants gave written informed consent prior to study inclusion.

Provenance and peer review Not commissioned; externally peer reviewed.

Open Access This is an Open Access article distributed in accordance with the Creative Commons Attribution Non Commercial (CC BY-NC 4.0) license, which permits others to distribute, remix, adapt, build upon this work non-commercially, and license their derivative works on different terms, provided the original work is properly cited and the use is non-commercial. See: <http://creativecommons.org/licenses/by-nc/4.0/>

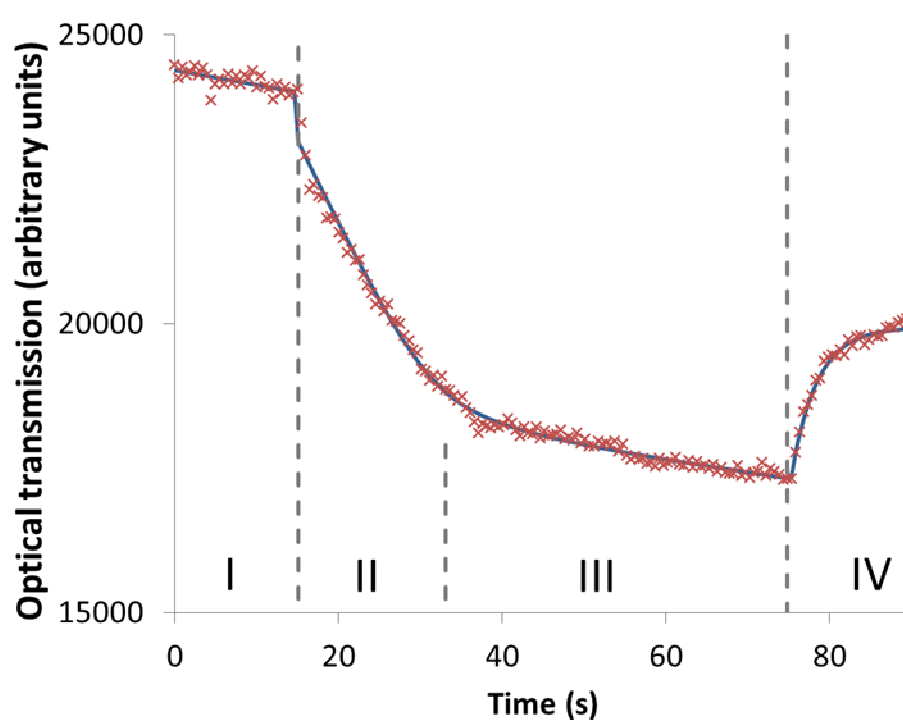
REFERENCES

- Schoels M, Knevel R, Aletaha D, *et al.* Evidence for treating rheumatoid arthritis to target: results of a systematic literature search. *Ann Rheum Dis* 2010;69:638–43.
- Uhlig T, Kvien TK, Pincus T. Test-retest reliability of disease activity core set measures and indices in rheumatoid arthritis. *Ann Rheum Dis* 2009;68:972–5.
- van Gestel AM, Prevoo ML, van 't Hof MA, *et al.* Development and validation of the European League Against Rheumatism response criteria for rheumatoid arthritis. Comparison with the preliminary American College of Rheumatology and the World Health Organization/International League Against Rheumatism Criteria. *Arthritis Rheum* 1996;39:34–40.
- Ton E, Bakker MF, Verstappen SM, *et al.* Look beyond the disease activity score of 28 joints (DAS28): tender points influence the DAS28 in patients with rheumatoid arthritis. *J Rheumatol* 2012;39:22–7.
- Jacobs JW, Ten Cate DF, van Laar JM. Monitoring of rheumatoid arthritis disease activity in individual patients: still a hurdle when implementing the treat-to-target principle in daily clinical practice. *Rheumatology (Oxford)* 2015;54:959–61.
- Brown AK, Quinn MA, Karim Z, *et al.* Presence of significant synovitis in rheumatoid arthritis patients with disease-modifying antirheumatic drug-induced clinical remission: evidence from an imaging study may explain structural progression. *Arthritis Rheum* 2006;54:3761–73.
- Smolen JS, Aletaha D, Bijlsma JW, *et al.* Treating rheumatoid arthritis to target: recommendations of an international task force. *Ann Rheum Dis* 2010;69:631–7.
- Sinex JE. Pulse oximetry: principles and limitations. *Am J Emerg Med* 1999;17:59–67.
- Beuthan J, Zabarylo U, Krause A, *et al.* RA diagnostics using laser-optical images and conventional X-rays (fused imaging). *Med Laser Appl* 2007;22:127–33.
- Prapavat V, Runge W, Mans J, *et al.* The development of a finger joint phantom for the optical simulation of early inflammatory rheumatic changes. *Biomed Tech* 1997;42:319–26.
- Lasker JM, Fong CJ, Ginat DT, *et al.* Dynamic optical imaging of vascular and metabolic reactivity in rheumatoid joints. *J Biomed Opt* 2007;12:052001.
- Werner SG, Langer HE, Ohrndorf S, *et al.* Inflammation assessment in patients with arthritis using a novel in vivo fluorescence optical imaging technology. *Ann Rheum Dis* 2012;71:504–10.
- Meier R, Thümel K, Moog P, *et al.* Detection of synovitis in the hands of patients with rheumatologic disorders: diagnostic performance of optical imaging in comparison with magnetic resonance imaging. *Arthritis Rheum* 2012;64:2489–98.
- Meier AJ, Rensen WH, de Bokx PK, *et al.* Potential of optical spectral transmission measurements for joint inflammation measurements in rheumatoid arthritis patients. *J Biomed Opt* 2012;17:081420.
- Backhaus M, Burmester GR, Gerber T, *et al.* Guidelines for musculoskeletal ultrasound in rheumatology. *Ann Rheum Dis* 2001;60:641–9.
- Szkudlarek M, Court-Payen M, Jacobsen S, *et al.* Interobserver agreement in ultrasonography of the finger and toe joints in rheumatoid arthritis. *Arthritis Rheum* 2003;48:955–62.
- Naredo E, D'Agostino MA, Wakefield RJ, *et al.* Reliability of a consensus-based ultrasound score for tenosynovitis in rheumatoid arthritis. *Ann Rheum Dis* 2013;72:1328–34.
- Schmidt WA, Schmidt H, Schicke B, *et al.* Standard reference values for musculoskeletal ultrasonography. *Ann Rheum Dis* 2004;63:988–94.
- Gärtner M, Mandl P, Radner H, *et al.* Sonographic joint assessment in rheumatoid arthritis: associations with clinical joint assessment during a state of remission. *Arthritis Rheum* 2013;65:2005–14.
- Witt M, Mueller F, Nigg A, *et al.* Relevance of grade 1 gray-scale ultrasound findings in wrists and small joints to the assessment of subclinical synovitis in rheumatoid arthritis. *Arthritis Rheum* 2013;65:1694–701.
- Meier R, Thümel K, Noël PB, *et al.* Synovitis in patients with early inflammatory arthritis monitored with quantitative analysis of dynamic contrast-enhanced optical imaging and MR imaging. *Radiology* 2014;270:176–85.
- Schäfer VS, Hartung W, Hoffstetter P, *et al.* Quantitative assessment of synovitis in patients with rheumatoid arthritis using fluorescence optical imaging. *Arthritis Res Ther* 2013;15:R124.

- 23 Werner SG, Langer HE, Schott P, *et al*. Indocyanine green-enhanced fluorescence optical imaging in patients with early and very early arthritis: a comparative study with magnetic resonance imaging. *Arthritis Rheum* 2013;65: 3036–44.
- 24 Harrell FE Jr, Lee KL, Mark DB. Multivariable prognostic models: issues in developing models, evaluating assumptions and adequacy, and measuring and reducing errors. *Stat Med* 1996;15:361–87.
- 25 Altman DG, Vergouwe Y, Royston P, *et al*. Prognosis and prognostic research: validating a prognostic model. *BMJ* 2009;338:b605.
- 26 van de Stadt LA, Bos WH, Meursinge Reynders M, *et al*. The value of ultrasonography in predicting arthritis in auto-antibody positive arthralgia patients: a prospective cohort study. *Arthritis Res Ther* 2010;12:R98.
- 27 Ohrndorf S, Fischer IU, Kellner H, *et al*. Reliability of the novel 7-joint ultrasound score: results from an inter- and intraobserver study performed by rheumatologists. *Arthritis Care Res* 2012;64:1238–43.
- 28 Dopazo González N, Ten Cate DF, Swen WA, *et al*. The most reliable probe position in the ultrasonographic examination of the wrist in rheumatoid arthritis. *Clin Exp Rheumatol* 2012;30:566–9.

Supplementary Figure 1. The optical response curve.

The recorded intensity of each pixel in a region of interest (ROI) versus the measurement time was fitted to a curve representing the response to inflation and deflation of the pressure cuff. Phase I baseline transmission (inflation of the cuff to 5 mmHg for the duration of 15 seconds), phase II and III inflation of the cuff to 50 mmHg during 60 seconds and phase IV after deflation of the cuff to 5 mmHg during 15 seconds.



New imaging techniques may help to assess disease activity in RA

New imaging techniques may offer hope for quicker and cheaper and less invasive imaging in people with rheumatoid arthritis, allowing disease activity and progression to be more closely monitored.

INTRODUCTION

Rheumatoid arthritis is a chronic inflammatory disease that affects a person's joints and sometimes their internal organs, causing pain and disability. Rheumatoid arthritis can cause inflammation in the lining of joints (the synovium). This inflammation is known as synovitis.

Imaging techniques allow doctors to see inside the joints to assess any damage and to monitor disease activity and progression (worsening). Common imaging techniques include X-ray, magnetic resonance imaging (MRI) and ultrasound, but these can be expensive and time consuming, and may not always be used.

Optical spectral transmission (shortened to OST) is a new, non-invasive imaging technique that uses light from a special machine to measure synovitis. Other techniques that use light to measure synovitis also require the person to have an infusion of a special dye into their bloodstream, but OST can take the measurement simply by shining light on the skin and recording the way in which it is reflected back. As well as being non-invasive, OST may be quicker and cheaper to use than other imaging techniques.

WHAT DID THE AUTHORS HOPE TO FIND?

The authors wanted to test OST to see whether it could be used to measure disease activity in people with rheumatoid arthritis. They also hoped to find out whether it would give the same results as traditional physical examination and other imaging techniques.

WHO WAS STUDIED?

The authors tested the OST imaging technique in 59 people with known rheumatoid arthritis and 10 people with non-inflammatory arthralgia (joint pain) of unknown cause.

HOW WAS THE STUDY CONDUCTED?

The study was conducted in patients from two clinics in the Netherlands. Each patient had an OST performed on their wrists and hand joints. To compare against, each patient also had a physical examination by a doctor, and a traditional ultrasound. Some people who were in remission (showing no symptoms of their rheumatoid arthritis) also had an MRI for comparison.

WHAT WERE THE MAIN FINDINGS OF THE STUDY?

The authors found that OST shows similar results to physical examination, ultrasound and MRI. OST works better in the small hand joints than larger joints in the wrists.

ARE THESE FINDINGS NEW?

Yes, this was a pilot study of OST in people with rheumatoid arthritis.

HOW RELIABLE ARE THE FINDINGS?

This study does have some limitations. One possible limitation is the use of people with arthralgia as a control group, because this condition can turn into inflammatory arthritis, and so they may have already had some inflammation present in their joints. Additionally, all the OST measurements were taken by just one person, so it was not possible to work out whether there is a difference between how different people might read and interpret the outputs. Finally, the way the authors designed the statistical analysis may have affected the results. However, they tried to reduce the effects of this by using a fairly large number of patients, and altering how the results were validated. As such, the authors are confident that the results are reliable.

WHAT DO THE AUTHORS PLAN ON DOING WITH THIS INFORMATION?

The authors are planning more studies to investigate the use of OST in people with rheumatoid arthritis. They hope to be able to automate the system so that it does not rely on a person to read the results, and also to work out how sensitive the method will be to small changes.

WHAT DOES THIS MEAN FOR ME?

If you have rheumatoid arthritis, you may have received an ultrasound, MRI or X-ray to check on the progress of your disease. In the future, newer imaging techniques may be used that are quicker and cheaper. However, although OST was able to detect inflammation in people with rheumatoid arthritis, the method is still in early development, and will need to be tested in larger groups before it becomes widely available.

Disclaimer: This is a summary of a scientific article written by a medical professional (“the Original Article”). The Summary is written to assist non medically trained readers to understand general points of the Original Article. It is supplied “as is” without any warranty. You should note that the Original Article (and Summary) may not be fully relevant nor accurate as medical science is constantly changing and errors can occur. It is therefore very important that readers not rely on the content in the Summary and consult their medical professionals for all aspects of their health care and only rely on the Summary if directed to do so by their medical professional. Please view our full Website Terms and Conditions. <http://www.bmj.com/company/legal-information/>

Date prepared: March 2016

Summary based on research article published on: 9 October 2015

From: van Onna M. *et al.* Assessment of disease activity in patients with rheumatoid arthritis using optical spectral transmission measurements, a non-invasive imaging technique. *Ann Rheum Dis* 2016;75:511–18. doi:10.1136/annrheumdis-2015-207315

Copyright © 2016 BMJ Publishing Group Ltd & European League Against Rheumatism. Medical professionals may print copies for their and their patients and students non commercial use. Other individuals may print a single copy for their personal, non commercial use. For other uses please contact our [Rights and Licensing Team](#).