

# EULAR recommendations for the use of imaging in the diagnosis and management of spondyloarthritis in clinical practice

P Mandl,<sup>1</sup> V Navarro-Compán,<sup>2,3</sup> L Terslev,<sup>4</sup> P Aegerter,<sup>5</sup> D van der Heijde,<sup>2</sup> M A D'Agostino,<sup>6</sup> X Baraliakos,<sup>7</sup> S J Pedersen,<sup>8</sup> A G Jurik,<sup>9</sup> E Naredo,<sup>10</sup> C Schueller-Weidekamm,<sup>11</sup> U Weber,<sup>12</sup> M C Wick,<sup>13</sup> P A C Bakker,<sup>2</sup> E Filippucci,<sup>14</sup> P G Conaghan,<sup>15</sup> M Rudwaleit,<sup>16</sup> G Schett,<sup>17</sup> J Sieper,<sup>16</sup> S Tarp,<sup>18</sup> H Marzo-Ortega,<sup>15</sup> M Østergaard<sup>4</sup>

**Handling editor** Tore K Kvien

► Additional material is published online only. To view please visit the journal online (<http://dx.doi.org/10.1136/annrheumdis-2014-206971>).

For numbered affiliations see end of article.

## Correspondence to

Dr Peter Mandl, Division of Rheumatology, Medical University of Vienna, 18-20 Währinger Gürtel, Vienna 1090, Austria; [peter.mandl@meduniwien.ac.at](mailto:peter.mandl@meduniwien.ac.at)

Received 11 November 2014

Revised 23 February 2015

Accepted 7 March 2015

Published Online First

2 April 2015

## ABSTRACT

A taskforce comprised of an expert group of 21 rheumatologists, radiologists and methodologists from 11 countries developed evidence-based recommendations on the use of imaging in the clinical management of both axial and peripheral spondyloarthritis (SpA). Twelve key questions on the role of imaging in SpA were generated using a process of discussion and consensus. Imaging modalities included conventional radiography, ultrasound, magnetic resonance imaging, computed tomography (CT), positron emission tomography, single photon emission CT, dual-emission x-ray absorptiometry and scintigraphy. Experts applied research evidence obtained from systematic literature reviews using MEDLINE and EMBASE to develop a set of 10 recommendations. The strength of recommendations (SOR) was assessed by taskforce members using a visual analogue scale. A total of 7550 references were identified in the search process, from which 158 studies were included in the systematic review. Ten recommendations were produced using research-based evidence and expert opinion encompassing the role of imaging in making a diagnosis of axial SpA or peripheral SpA, monitoring inflammation and damage, predicting outcome, response to treatment, and detecting spinal fractures and osteoporosis. The SOR for each recommendation was generally very high (range 8.9–9.5). These are the first recommendations which encompass the entire spectrum of SpA and evaluate the full role of all commonly used imaging modalities. We aimed to produce recommendations that are practical and valuable in daily practice for rheumatologists, radiologists and general practitioners.

The group of spondyloarthritis comprises a number of closely related rheumatic diseases with common clinical features,<sup>1</sup> including ankylosing spondylitis (AS), psoriatic arthritis (PsA), arthritis/spondylitis related to inflammatory bowel disease and reactive arthritis (ReA).<sup>2–6</sup>

In addition to these subtypes, patients with spondyloarthritis (SpA) can also be grouped into two categories based on their predominant clinical presentation: axial and peripheral.<sup>1 2</sup> This division was reflected in the Assessment of Spondyloarthritis International Society (ASAS) classification criteria, which separated axial and peripheral SpA (axSpA

and pSpA).<sup>7 8</sup> Imaging is a key component of classification criteria for SpA, primarily due to the lack of specific clinical symptoms as well as varying disease activity over time. For example, radiographic sacroiliitis is an essential part of the internationally accepted modified New York criteria for AS.<sup>4</sup> Significant advances have been made within the field of imaging in SpA over the past decade. Several imaging modalities are now available that may aid in the diagnosis and monitoring of both axSpA and pSpA as well as in predicting structural damage and treatment response. However, conventional radiography (radiography) only visualises the late structural consequences of the inflammatory process, while the early inflammatory changes can be detected by MRI, often several years before the appearance of sacroiliitis on radiography.<sup>9</sup> Accordingly, MRI was incorporated in the ASAS classification criteria for axSpA as well as pSpA.<sup>7 8</sup>

Reflecting the perceived need for developing evidence-based recommendations on the use of musculoskeletal imaging in the clinical management of SpA, a European League Against Rheumatism (EULAR) taskforce was convened to develop evidence-based recommendations on the use of musculoskeletal imaging in the clinical management of SpA, for rheumatologists, radiologists and general practitioners.

## METHODS

An expert group of 21 rheumatologists, radiologists and methodologists representing 11 countries formed the taskforce. The objectives were to formulate key clinical questions relating to the role of imaging in SpA, to identify and critically appraise the available evidence, and to generate recommendations based on both evidence and expert opinion.

At the initial taskforce meeting, members proposed clinically relevant questions related to key aspects of the use of imaging in SpA. Twelve final research questions (Q1–12) were formulated and agreed upon by consensus, encompassing the full spectrum of the role of imaging in diagnosing axSpA or pSpA, monitoring inflammation and damage, predicting outcome and response to treatment, as well as detecting spinal fractures and



**To cite:** Mandl P, Navarro-Compán V, Terslev L, et al. *Ann Rheum Dis* 2015;**74**:1327–1339.

osteoporosis (see online supplementary material S1: research questions).

Three systematic literature searches were performed using MEDLINE and EMBASE databases. The first search summarised research questions 1–10 (Q1–10) (questions on the diagnostic, monitoring and predictive role of imaging), while the research question on the detection of spinal fractures (Q11) and that on the detection of osteoporosis (Q12) were covered by independent searches. Specific medical subject headings and additional keywords were used to identify all relevant studies (see online supplementary material S2: search strategy). In addition, abstract archives of relevant international rheumatology and radiology meetings (2011, 2012) as well as the bibliographies of included papers were hand searched for evidence of other studies for inclusion. Titles and abstracts of all citations identified were screened, and potentially relevant articles were reviewed in full text using predetermined inclusion and exclusion criteria.

Studies published in English up to January 2013, on the use of imaging in adults ( $\geq 18$  years) with a suspected or established clinical diagnosis of SpA (including inflammatory and low back pain for the research question on the diagnostic role of imaging in axSpA), axSpA or pSpA (and suspicion of spinal (vertebral) fracture with regard to Q11), were included. Imaging modalities included radiography, ultrasound (US), MRI, CT, positron emission tomography, single-photon emission CT (SPECT), quantitative sacroiliac (SI) joint scintigraphy (QSS) and dual-energy X-ray absorptiometry (DXA). Study types included randomised controlled trials (RCTs), systematic reviews, controlled clinical trials, cohort, case-control and diagnostic studies.

Studies not in English language, those including patients  $\leq 18$  years of age and those reporting data acquired from  $< 20$  control patients for questions 1–2 on the diagnostic role of imaging) were excluded. Quality assessment of all included studies was done using the QUADAS-2 tool<sup>10</sup> and presented graphically for each research question.<sup>11</sup>

Data from the literature reviews were categorised and presented at the second taskforce meeting according to study design using a hierarchy of evidence in descending order according to quality.<sup>12</sup> The literature review was conducted by PM, VNC and PB. Data extraction for each research question was reviewed by at least two of the above-mentioned taskforce members. Greater emphasis was given to the best available evidence, although all data were collected and reviewed. Expert evidence was cited only when available research evidence was lacking. The experts finally formulated 10 recommendations based on the 12 clinical questions through a process of discussion and consensus, followed by final wording adjustments by email exchange. The finally perceived strength of recommendation (SOR) for each proposition was scored by the experts using a 0–10 visual analogue scale (VAS; 0=not recommended at all, 10=fully recommended) with data from the quality assessment. Scores reflected both research evidence and clinical expertise.<sup>13</sup>

A research agenda was agreed upon by consensus following the presentation of the literature reviews.

## RESULTS

The combined search for Q1–12 resulted in a total of 7550 records, of which a total of 158 articles were finally selected for inclusion in the systematic literature review. Articles that were relevant to  $> 1$  research question were included in the review more than once. The flow charts showing the detailed results of all three searches are shown in online supplementary figure S3.

The number of articles included for each research question is shown in online supplementary table S4. Taskforce members produced 10 recommendations based on a process of discussion. The recommendations, SOR (mean VAS and 95% CI) and level of evidence are presented in table 1. A full reference list for articles included in each recommendation is shown in online supplementary material S5.

## Recommendations

### Recommendation 1: diagnosing axial SpA

A. In general, conventional radiography of the SI joints is recommended as the first imaging method to diagnose sacroiliitis as part of axial SpA. In certain cases, such as young patients and those with short symptom duration, MRI of the SI joints is an alternative first imaging method.

B. If the diagnosis of axial SpA cannot be established based on clinical features and conventional radiography, and axial SpA is still suspected, MRI of the SI joints is recommended. On MRI, both active inflammatory lesions (primarily bone marrow oedema (BME)) and structural lesions (such as bone erosion, new bone formation, sclerosis and fat infiltration) should be considered. MRI of the spine is not generally recommended to diagnose axial SpA.

C. Imaging modalities other than conventional radiography and MRI are not generally recommended in the diagnosis of axial SpA\*.

\*CT may provide additional information on structural damage if conventional radiography is negative and MRI cannot be performed. Scintigraphy and US are not recommended for diagnosis of sacroiliitis as part of axial SpA.

Strength of recommendation: 9.5 (95% CI 9.2 to 9.8).

Twenty-five studies evaluated the diagnostic utility of various imaging modalities in axSpA.<sup>14–38</sup> Five studies reported on the diagnostic utility of radiography.<sup>14–18</sup> They demonstrated varying sensitivity (SE) and specificity (SP) of radiography in diagnosing sacroiliitis in inflammatory back pain (IBP)/suspicion of SpA, while one observational study reported an SE of 0.84 and an SP of 0.75 in diagnosing sacroiliitis in AS.<sup>14–18</sup> A single study reported only fair agreement between radiography and CT in suspected sacroiliitis and many false positive results using radiography.<sup>18</sup> Two studies reported higher SE for CT than radiography for diagnosing sacroiliitis (1 in AS, 1 in suspected SpA).<sup>15 17</sup>

Thirteen studies evaluated the diagnostic utility of MRI demonstrating varying SE and overall higher SP in patients with IBP or those with suspicion of SpA (table 2).<sup>19–31</sup> Three studies reported SE (0.73–0.9) and SP (0.9–0.97) for SI joint BME on MRI in established AS.<sup>22 23 25</sup> Wick *et al*<sup>26</sup> reported an SE of 0.11 and an SP of 0.93 for MRI SI joint erosions for diagnosis of AS, while Weber *et al*<sup>25</sup> reported that the combined features of SI joint erosion and/or BME increased SE to 0.98–0.96 compared with BME alone (0.91–0.83) without reducing SP and the area under the curve for diagnosis of AS. Heuft-Dorenborch *et al* found that initial assessment of structural changes by radiography followed by MRI assessment of inflammation with negative radiography gives the highest returns for detecting involvement of the SI joint in patients with recent IBP.<sup>27</sup> Finally, two studies found MRI of the SI joint superior to QSS or radiography for diagnosing sacroiliitis in IBP and SpA.<sup>14 33</sup>

With regard to MRI of the spine, three studies reported SE of and SP for corner fat lesions and corner inflammatory lesions (CILs) in patients suspected for axSpA,<sup>29 30 31</sup> while two studies reported SE and SP in established AS.<sup>31 32</sup> Finally, Weber *et al*<sup>32</sup> have demonstrated that spinal MRI adds little incremental value

**Table 1** EULAR recommendations for the use of imaging in the diagnosis and management of spondyloarthritis in clinical practice

|   | SOR           | LOE |
|---|---------------|-----|
| 1 <i>Axial SpA: diagnosis</i><br>A. In general, conventional radiography of the SI joints is recommended as the first imaging method to diagnose sacroiliitis as part of axial SpA. In certain cases, such as young patients and those with short symptom duration, MRI of the SI joints is an alternative first imaging method.<br>B. If the diagnosis of axial SpA cannot be established based on clinical features and conventional radiography, and axial SpA is still suspected, MRI of the SI joints is recommended. On MRI, both active inflammatory lesions (primarily bone marrow oedema) and structural lesions (such as bone erosion, new bone formation, sclerosis and fat infiltration) should be considered. MRI of the spine is not generally recommended to diagnose axial SpA.<br>C. Imaging modalities, other than conventional radiography and MRI are generally not recommended in the diagnosis of axial SpA*. | 9.5 (9.2–9.8) | III |
| 2 <i>Peripheral SpA: diagnosis</i><br>When peripheral SpA is suspected, US or MRI may be used to detect peripheral enthesitis, which may support the diagnosis of SpA. Furthermore, US or MRI might be used to detect peripheral arthritis, tenosynovitis and bursitis.   | 9.4 (9.0–9.8) | III |
| 3 <i>Axial SpA: monitoring activity</i><br>MRI of the SI joints and/or the spine may be used to assess and monitor disease activity in axial SpA, providing additional information on top of clinical and biochemical assessments. The decision on when to repeat MRI depends on the clinical circumstances. In general, STIR sequences are sufficient to detect inflammation and the use of contrast medium is not needed.   | 9.2 (8.8–9.6) | Ib  |
| 4 <i>Axial SpA: monitoring structural changes</i><br>Conventional radiography of the SI joints and/or spine may be used for long-term monitoring of structural damage, particularly new bone formation, in axial SpA. If performed, it should not be repeated more frequently than every second year. MRI may provide additional information.   | 9.3 (8.8–9.8) | Ib  |
| 5 <i>Peripheral SpA: monitoring activity</i><br>US and MRI may be used to monitor disease activity (particularly synovitis and enthesitis) in peripheral SpA, providing additional information on top of clinical and biochemical assessments. The decision on when to repeat US/MRI depends on the clinical circumstances. US with high-frequency colour or power Doppler is sufficient to detect inflammation and the use of US contrast medium is not needed.  | 9.3 (8.9–9.7) | Ib  |
| 6 <i>Peripheral SpA: monitoring structural changes</i><br>In peripheral SpA, if the clinical scenario requires monitoring of structural damage, then conventional radiography is recommended. MRI and/or US might provide additional information.   | 8.9 (8.4–9.4) | III |
| 7 <i>Axial SpA: predicting outcome/severity</i><br>In patients with ankylosing spondylitis† (not non-radiographic axial SpA), initial conventional radiography of the lumbar and cervical spine is recommended to detect syndesmophytes, which are predictive of development of new syndesmophytes. MRI (vertebral corner inflammatory or fatty lesions) may also be used to predict development of new radiographic syndesmophytes.  | 9.0 (8.5–9.5) | Ib  |
| 8 <i>Axial SpA: predicting treatment effect</i><br>Extensive MRI inflammatory activity (bone marrow oedema), particularly in the spine in patients with ankylosing spondylitis, might be used as a predictor of good clinical response to anti-TNF-alpha treatment in axial SpA. Thus, MRI might aid in the decision of initiating anti-TNF-alpha therapy, in addition to clinical examination and CRP.   | 8.9 (8.3–9.5) | Ib  |
| 9 <i>Spinal fracture</i><br>When spinal fracture in axial SpA is suspected, conventional radiography is the recommended initial imaging method. If conventional radiography is negative, CT should be performed. MRI is an additional imaging method to CT, which can also provide information on soft tissue lesions.  | 9.3 (8.9–9.7) | IV  |
| 10 <i>Osteoporosis</i><br>In patients with axial SpA without syndesmophytes in the lumbar spine on conventional radiography, osteoporosis should be assessed by hip DXA and AP-spine DXA. In patients with syndesmophytes in the lumbar spine on conventional radiography, osteoporosis should be assessed by hip DXA, supplemented by either spine DXA in lateral projection or possibly QCT of the spine.   | 9.4 (9.0–9.8) | III |

\*CT may provide additional information on structural damage if conventional radiography is negative and MRI cannot be performed. Scintigraphy and US are not recommended for diagnosis of sacroiliitis as part of axial SpA.

†That is, radiographic axial spondyloarthritis.

Level of evidence (LOE): Ia, evidence for meta-analysis of randomised controlled trials; Ib, evidence from at least one randomised controlled trial; IIa, evidence from at least one controlled study without randomisation; IIb, evidence from at least one other type of quasi-experimental study; III, evidence from non-experimental descriptive studies, such as comparative studies, correlation studies and case-control studies; IV, evidence from expert committee reports or opinions or clinical experience of respected authorities, or both. AP, anterior-posterior; CRP, C-reactive protein; DXA, dual-energy X-ray absorptiometry; EULAR, European League Against Rheumatism; nr-axSpA, non-radiographic axial spondyloarthritis; QCT, quantitative CT; SI, sacroiliac; SIJ, sacroiliac joints; SOR, strength of recommendation; SpA, spondyloarthritis; STIR, short tau inversion recovery; TNF-alpha, tumour necrosis factor alpha; US, ultrasonography.

compared with MRI of the SI joint alone in terms of lesion detection and classification of patients with early SpA. Four studies reported that QSS has low SE for diagnosis of sacroiliitis in patients with IBP.<sup>14 33–35</sup> Klauser *et al*<sup>36 37</sup> reported that contrast-enhanced US is a sensitive and specific tool for diagnosing active sacroiliitis in patients with IBP and AS. One study reported that pulsatile monophasic colour Doppler US detects sacroiliitis in patients with AS.<sup>38</sup> Quality assessment is reported in online supplementary figure S6.1; of note risk of patient selection bias and applicability concerns with regard to patient selection were high in 52% and 36% of the included manuscripts, respectively.

**Recommendation 2: diagnosing peripheral SpA**

When peripheral SpA is suspected, US or MRI may be used to detect peripheral enthesitis, which may support the diagnosis of

SpA. Furthermore, US or MRI might be used to detect peripheral arthritis, tenosynovitis and bursitis.

Strength of recommendation: 9.4 (95% CI 9.0 to 9.8)

Nine studies evaluated grey-scale and/or power Doppler US (GSUS/PDUS, respectively) for assessment of entheses in patients with established pSpA<sup>39–47</sup> using clinical examination as gold standard. Eight studies evaluated multiple entheses,<sup>39–46</sup> while one study evaluated only the Achilles tendon.<sup>47</sup> One study reported that PDUS has an SE of 0.76 and an SP of 0.81 in suspected SpA,<sup>41</sup> while four studies reported varying SE and overall higher SP in established PsA.<sup>39 45–47</sup> Four studies reported an SE of 0.83–0.98 and an SP of 0.48–0.9 for PDUS assessment in established pSpA.<sup>40–43</sup> Finally, Feydy *et al*<sup>44</sup> reported that MRI of the heel had an SP of 0.94 but SE of 0.22 for discriminating between patients with SpA and controls.

**Table 2** Recommendation 1: summary of studies on the use of MRI in diagnosing axial spondyloarthritis

| Studies                                     | No. | Study population   | Gold standard      | SIJ/spine     | MRI lesion             | SE   | SP   | +LR  | -LR  |
|---|-----|--------------------|--------------------|---------------|------------------------|------|------|------|------|
| Longitudinal/RCT                            |     |                    |                    |               |                        |      |      |      |      |
| Bennett <i>et al</i> <sup>19</sup>          | 50  | SpA                | X-ray              | SIJ           | Grade 3 SI+HLA27 27B27 | 0.62 | 0.92 | 7.7  | 0.41 |
| Marzo-Ortega <i>et al</i> <sup>20</sup>     | 76  | IBP (NSBP, HC)     | Clinical diagnosis | SIJ           | Grade 1 SI             | 0.82 | 0.43 | 1.4  | 0.41 |
|   |     |                    |                    |               | Grade 2 SI             | 0.73 | 1.0  | ∞    | 0.73 |
| Oostveen <i>et al</i> <sup>21</sup>         | 25  | IBP                | X-ray              | SIJ           | Grade ≥2 SI            | 0.85 | 0.47 | 1.6  | 0.31 |
| Cross-sectional/case-control                |     |                    |                    |               |                        |      |      |      |      |
| Weber <i>et al</i> <sup>22 23</sup>         | 187 | AS, IBP (NSBP, HC) | Clinical diagnosis | SIJ           | BME (AS)               | 0.9  | 0.97 | 44.6 | 0.92 |
|   |     |                    |                    |               | BME (IBP)              | 0.51 | 0.97 | 26   | 0.50 |
|   |     |                    |                    |               | BME+ERO                | 0.81 | 0.97 | 27   | 0.19 |
| Weber <i>et al</i> <sup>24 25</sup>         | 157 | AS, IBP (NSBP, HC) | Clinical diagnosis | SIJ           | BME                    | 0.73 | 0.9  | 7.3  | 0.3  |
|   |     |                    |                    |               | BME and/or ERO         | 0.82 | 0.9  | 8.2  | 0.2  |
|   |     |                    |                    |               | FI                     | 0.21 | 0.97 | 8.3  | 0.81 |
|   |     |                    |                    |               | FI with BME or ERO     | 0.24 | 0.97 | 9.2  | 0.78 |
| Heuft-Dorenbosch <i>et al</i> <sup>27</sup> | 68  | IBP                | X-ray              | SIJ           | chronic changes        | 0.49 | 0.97 | 16.3 | 0.52 |
| Weber <i>et al</i> <sup>30</sup>            | 95  | AS, IBP, (HC)      | Clinical diagnosis | Spine         | >2 CIL (AS)            | 0.69 | 0.94 | 12   | 0.32 |
|   |     |                    |                    |               | >2 CIL (IBP)           | 0.32 | 0.96 | 8    | 0.70 |
|   |     |                    |                    |               | LIL                    | 0.97 | 0.31 | 1.4  | 0.09 |
| Kim <i>et al</i> <sup>31</sup>              | 104 | AS (HC)            | Clinical diagnosis | Spine         | MRI corner sign        | 0.44 | 0.96 | 11   | 0.58 |
| Retrospective                               |     |                    |                    |               |                        |      |      |      |      |
| Wick <i>et al</i> <sup>26</sup>             | 179 | AS (various)       | Clinical diagnosis | SIJ           | ERO                    | 0.11 | 0.93 | 1.57 | 0.95 |
| Bennett <i>et al</i> <sup>28 29</sup>       | 185 | SpA (DA, IBP, HC)  | Clinical diagnosis | SIJ and spine | BME                    | 0.35 | 0.78 | 1.59 | 0.83 |
|   |     |                    |                    |               | >3 RLs                 | 0.33 | 0.97 | 12.4 | 0.69 |
|   |     |                    |                    |               | Posterior BME lesion   | 0.13 | 0.99 | 14.5 | 0.87 |
|   |     |                    |                    |               | ≥5 FRLs                | 0.22 | 0.98 | 12.6 | 0.79 |

The terms of the individual original publications have been used in the table.

AS, ankylosing spondylitis; BME, bone marrow oedema; CIL, corner inflammatory lesion; DA, degenerative arthropathy; ERO, erosion; FI, fatty infiltration; FRL, 'fatty Romanus' lesion; HC, healthy control; HLA27, human leucocyte antigen B27; IBP, inflammatory back pain; LIL, lateral segment inflammatory lesion; +LR, positive likelihood ratio; -LR, negative likelihood ratio; No., number of individuals included in the study; NSBP, non-specific back pain; RCT, randomised controlled trial; RL, 'Romanus' lesion; SE, sensitivity; SP, specificity; SI, sacroiliitis, SIJ, sacroiliac joints; SpA, spondyloarthritis.

Quality assessment is reported in online supplementary figure S6.2; of note risk of patient selection bias and applicability concerns with regard to the index test were high in 55% and 33% of included manuscripts, respectively.

**Recommendation 3: monitoring disease activity in axial SpA**

MRI of the SI joints and/or the spine may be used to assess and monitor disease activity in axial SpA, providing additional information on top of clinical and biochemical assessments. The decision on when to repeat MRI depends on the clinical circumstances. In general, short tau inversion recovery (STIR) sequences are sufficient to detect inflammation and the use of contrast medium is not needed.

Strength of recommendation: 9.2 (95% CI 8.8 to 9.6)

Thirty-four studies evaluated the utility of MRI in monitoring disease activity in axSpA.<sup>20 21 48-79</sup> Table 3 summarises and presents the results of longitudinal<sup>20 21 50 52-54 61 63 64 66-69 71 73 74 76</sup> as well as cross-sectional<sup>51 59 60 70 79</sup> studies evaluating correlation with accepted disease activity parameters (Bath Ankylosing Spondylitis Disease Activity Index (BASDAI), Ankylosing Spondylitis Disease Activity Score (ASDAS), C-reactive protein (CRP) and erythrocyte sedimentation rate (ESR)) or pain.

In addition, seven studies compared the utility of different MRI sequences (contrast-enhanced T1-weighted (T1Gd) and STIR), for monitoring disease activity in axial SpA,<sup>48 49 53 56 57 65 72</sup> six of which reported high levels of agreement or correlation between the two sequences.<sup>48 49 53 56 57 65</sup> A single longitudinal and two cross-sectional studies reported higher SE of STIR,<sup>49 53 65</sup> while a single longitudinal and two cross-sectional studies reported higher diagnostic confidence/reliability of the T1Gd-DPTA sequence.<sup>48 49 53</sup>

Regarding frequency of spinal MRI examination, two longitudinal studies reported significant changes detected already at 6

or 12 weeks<sup>50 72</sup> with similar results for both STIR and T1Gd sequences.<sup>72</sup> There is currently no evidence for how frequently MRI should be repeated for monitoring disease activity in axial SpA. Quality assessment is reported in online supplementary figure S6.3.

**Recommendation 4: monitoring structural changes in axial SpA**

Conventional radiography of the SI joints and/or spine may be used for long-term monitoring of structural damage, particularly new bone formation, in axial SpA. If performed, it should not be repeated more frequently than every second year. MRI may provide additional information.

Strength of recommendation: 9.3 (95% CI 8.8 to 9.8)

Twenty-three studies evaluated the utility of various imaging modalities in monitoring structural damage in axSpA.<sup>50 63 70-72 80-97</sup> Of 13 radiography studies, 10 reported correlation between radiographic changes and accepted measures of function (Bath Ankylosing Spondylitis Functional Index (BASFI), Bath Ankylosing Spondylitis Metrology Index (BASMI), metrological measures (chest expansion, occiput-to-wall distance, finger-to-floor distance, tragus-wall distance, Schober's test, spinal flexion, cervical rotation)) (table 4).<sup>63 81-83 85-87 93 94 96</sup>

Six studies compared various spine radiography scoring methods (Bath Ankylosing Spondylitis Radiology Index (BASRI), Stoke Ankylosing Spondylitis Spinal Score (SASSS), modified Stoke Ankylosing Spondylitis Spinal Score (mSASSS), Berlin X-ray score, Radiographic Ankylosing Spondylitis Spinal Score (RASSS)),<sup>83 84 87 92 93 96</sup> of which two reported mSASSS being superior to BASRI and SASSS.<sup>93 96</sup> Baraliakos *et al*<sup>83</sup> reported the RASSS method, which includes the thoracic segment, superior to mSASSS, while Ramiro *et al*<sup>92</sup> reported no advantage of RASSS over mSASSS. Taylor *et al*<sup>95</sup> reported correlation between CT changes and QSS in the SI joint.

**Table 3** Recommendation 3: summary of studies on the use of MRI in monitoring disease activity in axial spondyloarthritis

| Studies                                 | No. | Region    | MRI scoring method | Correlation |             |           |        |               |
|---|-----|-----------|--------------------|-------------|-------------|-----------|--------|---------------|
|   |     |           |                    | ASDAS       | BASDAI      | CRP       | ESR    | Pain          |
| Longitudinal/RCT                        |     |           |                    |             |             |           |        |               |
| Marzo-Ortega <i>et al</i> <sup>20</sup> | 76  | Spine     | LEEDS              | –           | NS          | NS        | –      | NS            |
| Oostveen <i>et al</i> <sup>21</sup>     | 25  | SIJ       | mNY                | –           | –           | OR 2.1    | OR 2.1 | OR 1.2        |
| Baraliakos <i>et al</i> <sup>50</sup>   | 40  | Spine     | ASspiMRI-a         | –           | NS          | NS        | NS     | –             |
| Bonel <i>et al</i> <sup>52</sup>        | 28  | Spine     | ASspiMRI-a         | –           | 0.41        | –         | –      | –             |
| Braun <i>et al</i> <sup>53</sup>        | 20  | Spine     | ASspiMRI-a/c       | –           | 0.49–0.6    | –         | –      | –             |
| Braun <i>et al</i> <sup>54</sup>        | 98  | Spine     | ASspiMRI-a         | 0.35        | NS          | 0.4       | –      | NS            |
| Lambert 2007 <sup>61</sup>              | 82  | Spine/SIJ | SPARCC             | –           | NS          | p=0.018   | –      | NS            |
| Machado <i>et al</i> <sup>63</sup>      | 221 | Spine     | ASspiMRI-a         | 0.14        | NS          | –         | –      | –             |
| Machado <i>et al</i> <sup>64</sup>      | 221 | Spine     | ASspiMRI-a         | 0.23        | NS          | 0.32      | –      | –             |
| Maksymowych <i>et al</i> <sup>66</sup>  | 68  | Spine     | SPARCC             | –           | NS          | 0.65–0.68 | –      | NS            |
| Maksymowych <i>et al</i> <sup>67</sup>  | 36  | Spine     | SPARCC             | –           | NS          | 0.45      | 0.44   | –             |
| Marzo-Ortega <i>et al</i> <sup>68</sup> | 42  | Spine/SIJ | LEEDS              | –           | p=0.04      | –         | –      | –             |
| Pedersen <i>et al</i> <sup>69</sup>     | 82  | Spine/SIJ | Berlin             | 0.46/0.31   | –0.41/–0.31 | NS        | –      | –             |
| Puhakka <i>et al</i> <sup>71</sup>      | 34  | SIJ       | BME                | –           | NS          | –         | –      | –             |
| Rudwaleit <i>et al</i> <sup>73</sup>    | 62  | Spine/SIJ | Berlin             | –           | NS          | NS        | NS     | NS            |
| Sieper <i>et al</i> <sup>74</sup>       | 20  | Spine     | ASspiMRI-a         | –           | 0.5         | NS        | NS     | –             |
| Song <i>et al</i> <sup>76</sup>         | 76  | Spine/SIJ | ASspiMRI-a/Berlin  | p=0.04      | –           | NS        | –      | –             |
| Visvanathan <i>et al</i> <sup>77</sup>  | 279 | Spine     | ASspiMRI-a         | –           | –           | p<0.001   | –      | –             |
| Cross-sectional/case-control            |     |           |                    |             |             |           |        |               |
| Blachier 2013 <sup>51</sup>             | 648 | Spine/SIJ | Dichotomous        | –           | –           | –         | –      | aOR 1.71–2.86 |
| Goh <i>et al</i> <sup>55</sup>          | 34  | Spine     | ASspiMRI-a         | –           | NS          | NS        | NS     | –             |
| Kiltz <i>et al</i> <sup>59</sup>        | 100 | Spine/SIJ | Berlin             | NS          | NS          | 0.22      | –      | –             |
| Konca <i>et al</i> <sup>60</sup>        | 50  | Spine     | ASspiMRI-a         | 0.37        | NS          | 0.33      | 0.39   | –             |
| Puhakka <i>et al</i> <sup>70</sup>      | 41  | SIJ       | BME enhancement    | –           | NS          | –         | –      | –             |
| Weber <i>et al</i> <sup>79</sup>        | 197 | ACW       | Dichotomous        | –           | –           | –         | –      | κ 0.21–0.33   |

The Spearman test for rank correlation is used for test of correlation, values are correlation coefficients (rho), if not otherwise indicated. p Values indicate the level of statistical significance.

aOR, adjusted odd ratio; ACW, anterior chest wall; AS, ankylosing spondylitis; ASDAS, Ankylosing Spondylitis Disease Activity Score; ASspiMRI-a/c, ankylosing spondylitis spine MRI score for activity; BASDAI, Bath Ankylosing Spondylitis Disease Activity Score; BME, bone marrow oedema; CRP, C-reactive protein; ESR, erythrocyte sedimentation rate; LEEDS, Leeds MRI scoring system; mNY, modified New York; MRI, magnetic resonance imaging; No., number of individuals included in the study; NS, not statistically significant; OR, odds ratio; RCT, randomised controlled trial; SIJ, sacroiliac joints; SPARCC, Spondyloarthritis Research Consortium of Canada Scoring System; –, not done.

Five studies reported correlation between changes over time in MRI and radiography and/or CT parameters of structural damage,<sup>71 84 88–90</sup> while Puhakka *et al*<sup>91</sup> found MRI and CT are superior to radiography. A single study reported correlation between spinal MRI and metrological measures,<sup>97</sup> while two reported no correlation.<sup>70 91</sup> One study reported correlation between MRI changes and BASMI,<sup>88</sup> whereas two studies reported no correlation with BASFI.<sup>70 97</sup> Akgul *et al*<sup>80</sup> reported that fatty infiltration of the paraspinal muscles on MRI correlates with metrological measures. Regarding the frequency of MRI examinations for the monitoring of structural changes under treatment with a tumour necrosis factor (TNF) inhibitor, Rudwaleit *et al*<sup>72</sup> reported no significant spinal or SI joint changes after 24 weeks, while Baraliakos *et al* reported significant deterioration in the mean Ankylosing Spondylitis spinal MRI chronicity score (ASspiMRI-c) in the placebo group at 48 weeks.<sup>50</sup> There is currently no evidence whether and if so how frequently MRI should be repeated for the monitoring of structural changes in axial SpA. Quality assessment is reported in online supplementary figure S6.4; of note risk of patient selection bias and applicability concerns with regard to patient selection were high in 43% and 30% of included manuscripts, respectively.

**Recommendation 5: monitoring disease activity in peripheral SpA**  
US and MRI may be used to monitor disease activity (particularly synovitis and enthesitis) in peripheral SpA, providing additional information on top of clinical and biochemical

assessments. The decision on when to repeat US/MRI depends on the clinical circumstances. US with high-sensitivity colour or power Doppler is sufficient to detect inflammation and the use of US contrast medium is not needed.

Strength of recommendation: 9.3 (95% CI 8.9 to 9.7)

Fifteen studies evaluated the utility of various imaging modalities in monitoring disease activity in pSpA,<sup>39 40 98–110</sup> of which 10 investigated GSUS/PDUS for the assessment of entheses (8 on multiple entheses, 2 on the Achilles tendon). Out of the 10 studies investigating GSUS/PDUS, only a single study was longitudinal,<sup>98</sup> while the remaining 9 were cross-sectional.<sup>39 40 99–105</sup> A single study reported correlation with BASDAI,<sup>99</sup> while four reported no correlation.<sup>98 100–102</sup> Aydin *et al*<sup>100</sup> reported correlation between grey-scale enthesal changes of the Achilles tendon and CRP, while five studies reported no correlation with CRP and/or ESR.<sup>98 101–104</sup> Hamdi *et al*<sup>99</sup> reported correlation between pain and power Doppler enthesal changes of the lower limb entheses, while Kiris *et al*<sup>102</sup> reported no correlation between PD and axial entheses.

Two studies reported correlation with swollen or tender joint count,<sup>39 104</sup> while a single study reported no correlation.<sup>40</sup> Hamdi *et al*<sup>99</sup> reported correlation with clinical enthesitis indices (Maastricht Ankylosing Spondylitis Score, Spondyloarthritis Research Consortium of Canada (SPARCC) Enthesitis Index), while two studies reported no correlation.<sup>39 98</sup> Two studies reported discrepancies in abnormal entheses detected by US versus clinical examination.<sup>40 105</sup>

**Table 4** Recommendation 4: summary of studies on the use of radiography in monitoring structural changes in axial spondyloarthritis

| Studies                               | No. | Region    | X-ray scoring method     | Correlation   |                   |  |  |
|---------------------------------------|-----|-----------|--------------------------|---------------|-------------------|--|--|
|                                       |     |           |                          | BASFI         | BASMI             | Metrological measures  | CT                                       |
| <b>Longitudinal/RCT</b>               |     |           |                          |               |                   |  |  |
| Machado <i>et al</i> <sup>63</sup>    | 214 | Spine     | mSASSS                   | 0.18; p=0.008 | 0.59; p<0.001     | –  | –  |
| Averns <i>et al</i> <sup>81</sup>     | 53  | Spine     | SASSS                    | –             | –                 | –0.396, p<0.01 (CE)<br>0.503, p<0.001 (OWD)<br>0.351, p<0.02 (FFD)<br>–0.690, p<0.0001 (Schober)<br>–0.717, p<0.0001 (total spinal movement) | –  |
| Baraliakos <i>et al</i> <sup>82</sup> | 82  | Spine     | mSASSS                   | NS            | 0.49–0.59; p=0.01 | –  | –  |
| Baraliakos <i>et al</i> <sup>83</sup> | 80  | Spine     | mSASSS                   | –             | 0.49              | NS   | –  |
| Creemers <i>et al</i> <sup>85</sup>   | 50  | Spine     | mSASSS                   | –             | –                 | p=0.05–0.0005 (CE, OWD, SF)  | –  |
| Salaffi <i>et al</i> <sup>83</sup>    | 95  | Spine     | mSASSS                   | p=0.02        | p=0.01            | –  | –  |
| Taylor <i>et al</i> <sup>84</sup>     | 70  | Spine/SIJ | Semi-quantitative        | –             | –                 | –0.40; p<0.05 (SF)   | 0.52; p<0.01 (spine) 0.75; p<0.001 (SIJ) |
| Wanders <i>et al</i> <sup>86</sup>    | 133 | Spine/SIJ | mSASSS<br>SASSS<br>BASRI | 0.41          | –                 | –0.77 (SF)<br>0.65 (OWD)<br>–0.76 (mSchober)   | –  |
| <b>Cross-sectional/case–control</b>   |     |           |                          |               |                   |  |  |
| Lee <i>et al</i> <sup>86</sup>        | 39  | Spine     | BASRI                    | –             | –                 | –  | 0.53–0.73 (p<0.001)                      |
| Lubrano <i>et al</i> <sup>87</sup>    | 77  | Spine     | BASRI<br>mSASSS          | NS            | 0.47; p<0.001     | 0.49, p<0.001 (CR)<br>0.34, p<0.01 (TWD)<br>0.49, p<0.001 (OWD)<br>–0.24, p<0.05 (mSchober)<br>0.37, p<0.01 (FFD)                            | –  |

The Spearman test for rank correlation is used for test of correlation, values are correlation coefficients (rho), if not otherwise indicated. p Values indicate the level of statistical significance.

BASFI, Bath Ankylosing Spondylitis Functional Index; BASMI, Bath Ankylosing Spondylitis Metrology Index; BASRI, Bath Ankylosing Spondylitis Functional Radiology Index; CE, chest expansion; CR, cervical rotation; FFD, finger-to-floor distance; mSASSS, modified Stoke Ankylosing Spondylitis Score; mSchober, modified Schober's test; No., number of individuals included in the study; NS, not statistically significant; OWD, occiput-wall distance; RCT, randomised controlled trial; SASSS, Stoke Ankylosing Spondylitis Score; SF, spinal flexion; SIJ, sacroiliac joints; TWD, tragus-to-wall distance; –, not done.

Four longitudinal<sup>106–109</sup> and a single cross-sectional<sup>110</sup> study evaluated the utility of MRI in monitoring disease activity in pSpA with three longitudinal studies reporting the psoriatic arthritis MRI score (PsAMRIS) and rheumatoid arthritis MRI score performing well regarding SE to change.<sup>106–108</sup> Tan *et al* found no correlation between BME (as scored by PsAMRIS) and clinical disease activity measures in a cross-sectional study.<sup>110</sup> There is currently no evidence whether and if so how frequently US and/or MRI should be repeated for the monitoring of disease activity in peripheral SpA. Quality assessment is reported in online supplementary figure S6.5; of note patient selection bias was high in 47% of included manuscripts.

**Recommendation 6: monitoring structural changes in peripheral SpA**

In peripheral SpA, if the clinical scenario requires monitoring of structural damage, then conventional radiography is recommended. MRI and/or US might provide additional information.

Strength of recommendation: 8.9 (95% CI 8.4 to 9.4)

Seven studies evaluated the utility of conventional radiography (CR) to monitor structural changes in pSpA,<sup>101 102 111–115</sup> with one study also evaluating PDUS<sup>102</sup> and an additional study evaluating MRI.<sup>110</sup> Among the studies assessing the utility of radiography, two reported correlation with the functional indices Health Assessment Questionnaire and/or Arthritis Impact Measurement Scales.<sup>114 115</sup> A longitudinal study on 74 patients with PsA reported correlation between clinical joint deformity, typical radiographic changes in PsA and the PsA-modified Sharp score.<sup>114</sup> A case–control study on 98 patients with ReA reported correlation between radiographic condylar erosions of the temporomandibular joint and patient-reported outcomes.<sup>112</sup> A cross-sectional study on 60 patients with AS reported correlation

between BASFI and both radiographic and sonographic signs of enthesitis,<sup>102</sup> while a cross-sectional study on 44 patients with SpA reported correlation between the SpA tarsal radiographic index and the Glasgow Ultrasound Enthesitis Score, but no correlation between the radiographic index and BASMI or BASRI.<sup>101</sup> Finally, Tan *et al*<sup>110</sup> reported correlation between MRI erosions/BME and CR erosions/joint space narrowing in 28 patients with PsA. Quality assessment is reported in online supplementary figure S6.6; of note risk of patient selection bias was high in 50% of included manuscripts. There is currently no evidence whether and if so how frequently US and/or MRI should be repeated for the monitoring of structural changes in peripheral SpA.

**Recommendation 7: predicting outcome/severity in axial SpA**

In patients with AS\* (not non-radiographic axial SpA), initial conventional radiography of the lumbar and cervical spine is recommended to detect syndesmophytes, which are predictive of development of new syndesmophytes. MRI (vertebral corner inflammatory or fatty lesions) may also be used to predict development of new radiographic syndesmophytes.

\*That is, radiographic axial spondyloarthritis.

Strength of recommendation: 9.0 (95% CI 8.5 to 9.5)

Seventeen publications were included.<sup>19 81 82 116–129</sup> All studies evaluating radiography reported that baseline radiographic change (syndesmophytes) predicts radiographic progression in AS.<sup>82 116 118 122 126 129</sup> Baraliakos *et al* reported that syndesmophytes/ankylosis, rather than erosion or sclerosis, were the features most frequently showing progression in AS.<sup>116</sup> Maksymowych *et al*<sup>122</sup> found that high baseline mSASSS (cut-off of 10 units; OR 18.6) was an independent predictor of 2-year progression in AS.

Six studies reported correlation between CILs or vertebral edge inflammation on MRI and subsequent radiographic syndesmophyte formation in patients with AS.<sup>117 119 120 123 124 128</sup> Madsen *et al*<sup>121</sup> reported correlation of baseline inflammation and subchondral fatty marrow deposition on MRI with radiographic progression in the SI joint of patients with AS.

In a 2-year longitudinal study, Pedersen *et al*<sup>124</sup> found that new syndesmophytes develop more frequently from vertebral corners where a CIL had completely resolved on follow-up, and that no single vertebral corner evolved into a new syndesmophyte where a CIL was persistently observed on both baseline and follow-up MRI. Along the same line, a 2-year longitudinal study of patients with axSpA/AS revealed an association between decreasing inflammation in the SI joint and the concomitant development of new syndesmophytes (OR 12.48).<sup>125</sup> In a 1-year longitudinal study, Song *et al*<sup>127</sup> presented a significant relationship between the disappearance of inflammation and the appearance of fatty lesions in the spine of patients with axSpA. Moreover, Baraliakos *et al*<sup>119</sup> showed that both spinal inflammation and fatty degeneration were associated with later syndesmophyte development but fatty degeneration showed the highest risk in AS. In contrast, a retrospective analysis of 100 patients with AS, inflammation (OR 5.8) emerged as a more significant predictor of new syndesmophytes than did fat infiltration (OR 1.9).<sup>120</sup> Finally, Bennett *et al*<sup>19</sup> reported no association between baseline BME on lumbar spine MRI and mSASSS progression after 8 years in patients with AS.

Averns *et al*<sup>81</sup> reported correlation between baseline QSS values and radiographic progression in the spine at follow-up (median: 9 years) in patients with AS. Quality assessment is reported in online supplementary figure S6.7.

#### Recommendation 8: predicting treatment effect in axial SpA

Extensive MRI inflammatory activity (BME), particularly in the spine in patients with AS, might be used as a predictor of good clinical response to anti-TNF-alpha treatment in axial SpA. Thus, MRI might aid in the decision of initiating anti-TNF-alpha therapy, in addition to clinical examination and CRP.

Strength of recommendation: 8.9 (95% CI 8.3 to 9.5)

A total of three studies were included. A longitudinal study of 62 patients with AS under treatment anti-TNF-alpha biologics reported a positive likelihood ratio of 6.7 for achieving BASDAI50 response in patients with a Berlin MRI spine score >11, while the absence of active inflammatory lesions in the spine was highly predictive of not achieving BASDAI50. Only a trend was found for the MRI SI joint score.<sup>73</sup> An RCT of 185 patients with non-radiographic axial SpA reported that a baseline SPARCC MRI score  $\geq 2$  for either the SI joint or the spine was associated with better response after 12 weeks of adalimumab.<sup>75</sup> An RCT including 40 human leucocyte antigen B27 (HLA-B27)-positive patients with MRI sacroiliitis found no significant difference in BASDAI changes between patients with mild versus moderate/severe MRI SI joint BME at baseline.<sup>130</sup> Quality assessment is reported in online supplementary figure S6.8; of note risk of patient selection bias, as well as of flow and timing and applicability concerns, was each high in 33% of included manuscripts.

#### Recommendation 9: spinal fracture

When spinal fracture in axial SpA is suspected, conventional radiography is the recommended initial imaging method. If conventional radiography is negative, CT should be performed. MRI is an additional imaging method to CT, which can also provide information on soft tissue lesions.

Strength of recommendation: 9.3 (95% CI 8.9 to 9.7)

Although no study met the inclusion criteria for this recommendation, two studies selected for full-text review were presented to the taskforce as they could provide some evidence (quality assessment however was not performed). The first study included 11 patients with AS and neurological symptoms after trauma to the neck region. CT and MRI detected all fractures while radiography detected 82% of them. Soft tissue injuries were detected in four patients, only by MRI.<sup>131</sup> The second study included 199 patients from the general population with suspected cervical spine injury. Twenty-one acute fractures were detected in 14 patients. Weighted average SE to detect acute fractures for MRI and radiography were 0.43 (95% CI 0.21 to 0.66) and 0.48 (95% CI 0.30 to 0.65), respectively. In contrast, weighted average SE to detect soft tissue injuries for MRI and radiography were 0.55 (95% CI 0.39 to 0.70) and 0.07 (95% CI 0.02 to 0.13), respectively.<sup>132</sup> In addition to its utility in imaging soft tissue, MRI allows the direct visualisation of the spinal cord and thus direct evaluation of spinal cord injuries.

#### Recommendation 10: osteoporosis

In patients with axial SpA without syndesmophytes in the lumbar spine on conventional radiography, osteoporosis should be assessed by hip DXA and anterior-posterior (AP)-spine DXA. In patients with syndesmophytes in the lumbar spine on conventional radiography, osteoporosis should be assessed by hip DXA, supplemented by either spine DXA in lateral projection or possibly quantitative CT (QCT) of the spine.

Strength of recommendation: 9.4 (95% CI 9.0 to 9.8)

A total of 42 studies were included,<sup>133-174</sup> while one additional study that did not meet the inclusion criteria but provided some evidence was also shown to the taskforce.<sup>175</sup> Only one study compared the diagnostic utility between two different techniques for detecting osteoporosis in SpA. This reported moderate SE (0.50-0.75) and SP (0.67-0.75) for quantitative US compared with DXA.<sup>133</sup> Three studies reported no additional value of quantitative US compared with DXA<sup>134-136</sup> while three studies compared QCT to DXA and reported that in patients with advanced AS osteoporosis is more frequently detected by QCT of the spine than using DXA of the spine<sup>137 175</sup> or the hip region.<sup>138</sup>

Moreover, 37 studies (32 in axSpA and 6 in PsA) provided data on the site for performing DXA.<sup>139-173</sup> In axSpA, 20 studies compared DXA at different sites for distinguishing between patients with AS and controls. Fifteen of these studies compared the AP/posterior-anterior (PA) projection at the spine versus the hip region but the results were inconsistent: six studies observed no differences,<sup>136 139-143</sup> eight reported results in favour of the hip<sup>135 144-150</sup> and one in favour of the spine.<sup>151</sup> Three studies compared the AP/PA versus the lateral projection at the spine and all reported that the lateral projection differentiated better between AS and controls.<sup>145 146 149</sup> Only four studies compared forearm DXA with other regions, all of them reporting data in favour of spine or hip<sup>137 142 152 153</sup> regions.

Furthermore, some studies also evaluated the possible influence of radiographic change, disease duration or disease activity in bone mineral density (BMD) determination at different regions (table 5). Most of the studies found the hip region being less influenced by radiographic change than the AP/PA projection of the spine.<sup>137 138 142 145 147 148 154 155 156</sup> Two studies reported the lateral spine projection being less influenced by radiographic change than the AP/PA projection.<sup>145 157</sup> Moreover, the majority of the studies found a positive correlation between BMD and disease duration with AP/PA projection of the spine while no correlation was found with the lateral projection or at hip. However, most of the studies did not observe

**Table 5** Recommendation 10: summary of studies evaluating different localisations to perform dual-energy X-ray absorptiometry in patients with axial spondyloarthritis

| (A)                                    |     | Radiographic damage (syndesmophytes/BASRI spine) |               |
|--|-----|--|---------------|
| Study                                  | No. | Results in favour of                             |               |
| N=11                                   |     | AP/PA spine                                      | Hip           |
| Devogelaer <i>et al</i> <sup>137</sup> | 70  |  | X             |
| Karberg 2005 <sup>138</sup>            | 103 |  | X             |
| Jun 2006 <sup>140</sup>                | 68  | ND   | ND            |
| Mullaji 1994 <sup>142</sup>            | 33  |  | X             |
| Gilgil 2005 <sup>145</sup>             | 20  |  | X             |
| Muntean 2011 <sup>147</sup>            | 44  |  | X             |
| Taylan 2012 <sup>148</sup>             | 55  |  | X             |
| Vasdev 2001 <sup>151</sup>             | 80  | ND   | ND            |
| Baek 2005 <sup>154</sup>               | 76  |  | X             |
| Capaci 2003 <sup>155</sup>             | 73  |  | X             |
| Donnelly 1994 <sup>156</sup>           | 87  |  | X             |
| N=2                                    |     | AP/PA spine                                      | Lateral spine |
| Gilgil 2005 <sup>145</sup>             | 20  |  | X             |
| Klingberg 2012 <sup>157</sup>          | 204 |  | X             |

| (B)                                 |     | Disease duration                             |               |
|-------------------------------------|-----|--|---------------|
| Study                               | No. | Correlation between BMD and disease duration |               |
| N=12                                |     | AP/PA spine                                  | Hip           |
| Arends 2011 <sup>170</sup>          | 198 | r=0.34                                       | NS            |
| El Maghroui 1999 <sup>173</sup>     | 80  | r=0.23                                       | NS            |
| Gilgil 2005 <sup>145</sup>          | 20  | r=0.52                                       | NS            |
| Grazio 2012 <sup>158</sup>          | 80  | r=0.05                                       | r=-0.361      |
| Jansen <i>et al</i> <sup>133</sup>  | 50  | No   | r=0.35        |
| Meirelles 1999 <sup>141</sup>       | 30  | r=0.65                                       | NS            |
| Mermerci 2010 <sup>146</sup>        | 100 | r=0.25                                       | r=-0.20       |
| Muntean 2011 <sup>147</sup>         | 44  | NS   | NS            |
| Speden <i>et al</i> <sup>135</sup>  | 66  | NS   | NS            |
| Taylan 2012 <sup>148</sup>          | 55  | r=0.30                                       | NS            |
| van der Weijden 2011 <sup>160</sup> | 130 | NS   | NS            |
| Vasdev 2011 <sup>151</sup>          | 80  | NS   | NS            |
| N=2                                 |     | AP/PA spine                                  | Lateral spine |
| Gilgil 2005 <sup>145</sup>          | 20  | r=0.52                                       | NS            |
| Mermerci 2010 <sup>146</sup>        | 100 | r=0.25                                       | NS            |

| (C)                                  |     | Disease activity  |               |
|--------------------------------------|-----|---|---------------|
| Study                                | No. | Correlation between BMD and disease activity parameters (ASDAS, BASDAI, CRP, ESR) |               |
| N=9                                  |     | AP/PA spine   | Hip           |
| Frediani <i>et al</i> <sup>134</sup> | 186 | NS  | NS            |
| Grazio 2012 <sup>158</sup>           | 80  | r=-0.30   | r=-0.22       |
| Mermerci 2010 <sup>146</sup>         | 100 | r=-0.24   | r=-0.24       |
| Mullaji 1994 <sup>142</sup>          | 33  | NS  | NS            |
| Muntean 2011 <sup>147</sup>          | 44  | NS  | NS            |
| Park 2008 <sup>159</sup>             | 35  | NS  | r=-0.49       |
| Taylan 2012 <sup>148</sup>           | 55  | NS  | NS            |
| van der Weijden 2011 <sup>160</sup>  | 130 | NS  | NS            |
| Vasdev 2011 <sup>151</sup>           | 80  | NS  | NS            |
| N=1                                  |     | AP/PA spine   | Lateral spine |
| Mermerci 2010 <sup>146</sup>         | 100 | r=-0.24   | r=-0.30       |

The Pearson test for rank correlation is used for test of correlation, values are correlation coefficients (r). AP, anterior-posterior; ASDAS, Ankylosing Spondylitis Disease Activity Score; BASDAI, Bath Ankylosing Spondylitis Disease Activity Score; BASRI, Bath Ankylosing Spondylitis Radiology Index; BMD, bone mineral density; CRP, C-reactive protein; ESR, erythrocyte sedimentation rate; ND, no statistically significant differences; NS, not statistically significant; PA, posterior-anterior.

correlation with AP/PA projection of the spine or at hip.<sup>135 141 146-148 151 158-160</sup> In patients with PsA, published data are scarce. Three studies compared the ability of AP/PA DXA of the spine with DXA of the hip to distinguish between patients with PsA and controls but the results were not consistent.<sup>134 161 162</sup> In patients with PsA, no correlation was observed between BMD detected by AP/PA DXA of the spine or the hip with disease duration<sup>134 163</sup> or with disease activity.<sup>134 164</sup>

**Box 1 Future research agenda**

1. To further investigate which imaging findings (imaging modality, anatomical location and type of pathology) provides the best clinical utility for early and accurate diagnosis of SpA.
  2. To further investigate which imaging findings (imaging modality, anatomical location and type of pathology) are best for monitoring peripheral and axial disease activity and structural damage in SpA in clinical practice.
  3. To further investigate which imaging findings (imaging modality, anatomical location and type of pathology) best predict the disease course (structural progression, pain, functional ability, health-related quality of life) and treatment response in SpA.
  4. To further investigate which imaging approaches best identify and monitor specific SpA-related features (such as enthesitis, dactylitis, synovitis and tenosynovitis, at different locations) in clinical practice.
  5. To further investigate the spatial and temporal relation between different imaging findings (imaging modality, anatomical location and type of pathology) providing further insight into the disease process of SpA, which may inform future clinical management of SpA.
  6. To investigate the importance of subclinical (detected only on imaging) axial and peripheral inflammation (including bone marrow oedema, synovitis, tenosynovitis and/or enthesitis), and if possible to identify thresholds to guide intervention. Subsequently to investigate the benefits (eg, on functional ability and quality of life) of incorporating such thresholds into treat-to-target strategies.
  7. To investigate new and/or alternative technical options to existing imaging technologies (US: eg, 3D/4D-transducers, Doppler quantification, elastosonography; MRI: eg, whole-body MRI, diffusion-weighted MRI and dynamic contrast-enhanced MRI with automated reading) as well as new imaging modalities (eg, optical imaging, new nuclear medicine techniques) of potential use in SpA in clinical practice.
  8. To further evaluate specific areas/joints to be assessed, timing of assessment(s) and the evaluation system to be employed in order to optimise the role of modern imaging modalities in the diagnosis, prognosis and outcome measurement of SpA.
  9. To investigate which imaging approach provides the best clinical utility for diagnosing spinal fractures, and the consequences thereof.
  10. To investigate which imaging approach provides the best clinical utility for diagnosis and monitoring of osteoporosis in SpA.
- SpA, spondyloarthritis; US, ultrasound; 3D, three-dimensional; 4D, four-dimensional.



Finally, only four longitudinal studies assessed BMD over time to monitor osteoporosis in patients with SpA.<sup>165–168</sup> In these studies, changes in BMD were observed after 1–2 years, especially in patients with active disease. Quality assessment is reported in online supplementary figure S6.9; of note risk of index test and reference standard bias were high in 86% and 88% of included manuscripts, respectively.

## DISCUSSION

These are the first recommendations produced by a EULAR taskforce on the use of imaging in SpA clinical practice. The group combined research-based evidence and expert opinion through a translational process among the experts from the presented literature-derived evidence to the final wording. Recommendations were primarily based on available research evidence with the exception of recommendation 9, which, lacking available data, was reliant on expert opinion. Finally, experts scored the SOR for each recommendation using data from the quality assessment.

We acknowledge that there is still a large amount of research required to optimise the use of imaging tools in the routine clinical practice of SpA.<sup>176</sup> We have summarised the most important topics for future research according to currently available evidence and clinical practice in box 1. These recommendations will likely need to be revisited in the future when important new evidence becomes available.<sup>12</sup>

In summary, we have developed 10 recommendations on various aspects of imaging in SpA. These are based on the best available evidence and clinical expertise supported by an international panel of experts. We aimed to produce recommendations that are practical and valuable in daily practice for rheumatologists, radiologists and general practitioners.

### Author affiliations

<sup>1</sup>Division of Rheumatology, Medical University of Vienna, Vienna, Austria

<sup>2</sup>Department of Rheumatology, Leiden University Medical Center, Leiden, The Netherlands

<sup>3</sup>University Hospital La Paz, Madrid, Spain

<sup>4</sup>Copenhagen Center for Arthritis Research, Center for Rheumatology and Spine Diseases, Copenhagen University Hospital at Glostrup, Copenhagen, Denmark

<sup>5</sup>Public Health Department, Ambroise Paré Hospital, Boulogne-Billancourt, France

<sup>6</sup>Department of Rheumatology, Ambroise Paré Hospital, Boulogne-Billancourt, France

<sup>7</sup>Rheumazentrum Ruhrgebiet, Herne, Germany

<sup>8</sup>Department of Rheumatology, Copenhagen University Hospital at Gentofte, Copenhagen, Denmark

<sup>9</sup>Department of Radiology, Aarhus University Hospital, Aarhus, Denmark

<sup>10</sup>Department of Rheumatology, Hospital General Universitario Gregorio Marañón, Madrid, Spain

<sup>11</sup>Department of Biomedical Imaging and Image-guided Therapy, Medical University of Vienna, Vienna, Austria

<sup>12</sup>King Christian 10th Hospital for Rheumatic Diseases, Gråsten, Denmark

<sup>13</sup>Department of Radiology, Karolinska University Hospital, Stockholm, Sweden

<sup>14</sup>Department of Rheumatology, Università Politecnica delle Marche, Ancona, Italy

<sup>15</sup>NIHR Leeds Musculoskeletal Biomedical Research Unit, Leeds Institute of Rheumatic and Musculoskeletal Medicine, University of Leeds, Leeds, UK

<sup>16</sup>Department of Rheumatology, Charité Universitätsmedizin, Berlin, Germany

<sup>17</sup>Department of Rheumatology and Immunology, University of Erlangen-Nuremberg, Erlangen, Germany

<sup>18</sup>Musculoskeletal Statistics Unit, Department of Rheumatology, The Parker Institute, Copenhagen University Hospital, Bispebjerg and Frederiksberg, Copenhagen, Denmark

**Contributors** PM and VN-C performed the literature review with help from ST, PA and PAB. PM and VN-C produced drafts of the manuscript with advice from OM and LT. All authors were involved in the conception of the study, in the analysis and interpretation of data, in the production of the recommendations and have reviewed the final manuscript.

**Competing interests** PM: consultancy/speaker fees: AbbVie, BMS, GE, Janssen, MSD, Pfizer, Roche, UCB; VN-C: consultancy/research grants: AbbVie, BMS, MSD, Novartis, Pfizer, Roche, UCB; LT: consultancy/speaker fees: AbbVie, GE, MSD, Roche,

UCB; PA: none; DvdH: consultancy/research grants: AbbVie, Amgen, AstraZeneca, Augurex, BMS, Boehringer Ingelheim, Celgene, Centocor, Chugai, Covagen, Daiichi, Eli-Lilly, Galapagos, GSK, Janssen Biologics, Merck, Novartis, Novo-Nordisk, Otsuka, Pfizer, Roche, Sanofi-Aventis, UCB, Vertex, Director of Imaging Rheumatology International; MAD'A: consultancy/speaker fees: AbbVie, BMS, MSD, Novartis, Pfizer, UCB; XB: consultancy/speaker fees: AbbVie, Amgen, Boehringer Ingelheim, BMS, Celgene, Centocor, Chugai, Janssen, MSD, Novartis, Pfizer, Sandoz, UCB; SJP: consultancy/speaker fees: AbbVie, MSD, Pfizer, Roche, UCB, Wyeth; research grants: AbbVie, MSD; AGJ: none; EN: research grants: MSD, Spanish Foundation of Rheumatology; speaker fees: Abbvie, BMS, ESAOTE, GE, Pfizer, Roche, UCB; CS-W: speaker fees: AbbVie, Eli-Lilly, Roche; UW: speaker fees: AbbVie, MSD; MCW: none; PACB: none; EF: speaker fees: Abbvie, BMS, MSD, UCB; PGC: consultancy/speaker fees: Abbvie, BMS, Janssen, Merck, Novartis, Pfizer, Roche; MR: consultancy: AbbVie, BMS; speaker fees: Chugai, MSD, Novartis, Pfizer, Roche, UCB; GS: none; JS: consultancy/speaker fees: Abbott, Janssen, Merck, Lilly, Novartis, Roche; research grants: Abbott, Merck, Pfizer; ST: speaker fees: AstraZeneca, Norpharma, Pfizer; research grants paid to institute: AbbVie, BMS, Mundipharma, Roche; HM-O: speaker fees/research grants: AbbVie, Celgene, Janssen, MSD, Novartis, Pfizer, UCB; MØ: research grant: Abbvie, Janssen, Merck; consultancy/speaker fees: Abbvie, BMS, Boehringer Ingelheim, Celgene, Centocor, Eli-Lilly, GSK, Hospira, Janssen, Merck, Mundipharma, Novartis, Orion, Pfizer, Roche, Takeda, UCB.

**Provenance and peer review** Not commissioned; externally peer reviewed.

## REFERENCES

- van Tubergen A, Weber U. Diagnosis and classification in spondyloarthritis: identifying a chameleon. *Nat Rev Rheumatol* 2012;8:253–61.
- Dougados M, van der Linden S, Juhlin R, et al. The European Spondylarthropathy Study Group preliminary criteria for the classification of spondylarthropathy. *Arthritis Rheum* 1991;34:1218–27.
- Amor B, Dougados M, Mijiyawa M. Criteria of the classification of spondylarthropathies [French]. *Rev Rhum* 1990;57:85–9.
- van der Linden S, Valkenburg HA, Cats A. Evaluation of diagnostic criteria for ankylosing spondylitis. A proposal for modification of the New York criteria. *Arthritis Rheum* 1984;27:361–8.
- Khan MA, van der Linden SM. A wider spectrum of spondylarthropathies. *Semin Arthritis Rheum* 1990;20:107–13.
- Khan MA, van der Linden SM, Kuschner I, et al. Spondylitic disease without radiological evidence of sacroiliitis in relatives of HLA-B27 positive patients. *Arthritis Rheum* 1985;28:40–3.
- Rudwaleit M, van der Heijde D, Landewé R, et al. The development of Assessment of SpondyloArthritis international Society classification criteria for axial spondyloarthritis (part II): validation and final selection. *Ann Rheum Dis* 2009;68:777–83.
- Rudwaleit M, van der Heijde D, Landewé R, et al. The Assessment of SpondyloArthritis International Society classification criteria for peripheral spondyloarthritis and for spondyloarthritis in general. *Ann Rheum Dis* 2011;70:25–31.
- Braun J, Bollow M, Eggens U, et al. Use of dynamic magnetic resonance imaging with fast imaging in the detection of early and advanced sacroiliitis in spondylarthropathy patients. *Arthritis Rheum* 1994;37:1039–45.
- Whiting PF, Rutjes AW, Westwood ME, et al. QUADAS-2: a revised tool for the quality assessment of diagnostic accuracy studies. *Ann Intern Med* 2011;155:529–36.
- McNally E, Keogh C, Galvin R, et al. Diagnostic accuracy of a clinical prediction rule (CPR) for identifying patients with recent-onset undifferentiated arthritis who are at a high risk of developing rheumatoid arthritis: A systematic review and meta-analysis. *Semin Arthritis Rheum* 2014;43:498–507.
- Dougados M, Betteridge N, Burmester GR, et al. EULAR standardised operating procedures for the elaboration, evaluation, dissemination, and implementation of recommendations endorsed by the EULAR standing committees. *Ann Rheum Dis* 2004;63:1172–6.
- Shekelle PG, Woolf SH, Eccles M, et al. Clinical guidelines: developing guidelines. *BMJ* 1999;318:593–6.
- Blum U, Buitrago-Tellez C, Mundinger A, et al. Magnetic resonance imaging (MRI) for detection of active sacroiliitis—a prospective study comparing conventional radiography, scintigraphy, and contrast enhanced MRI. *J Rheumatol* 1996;23:2107–15.
- Devauchelle-Pensec V, D'Agostino MA, Marion J, et al. Computed tomography scanning facilitates the diagnosis of sacroiliitis in patients with suspected spondylarthritis: results of a prospective multicenter French cohort study. *Arthritis Rheum* 2012;64:1412–19.
- Goie The HS, Steven MM, van der Linden SM, et al. Evaluation of diagnostic criteria for ankylosing spondylitis: a comparison of the Rome, New York and modified New York criteria in patients with a positive clinical history screening test for ankylosing spondylitis. *Br J Rheumatol* 1985;24:242–9.

- 17 van Tubergen A, Heuft-Dorenbosch L, Schulpen G, *et al.* Radiographic assessment of sacroiliitis by radiologists and rheumatologists: does training improve quality? *Ann Rheum Dis* 2003;62:519–25.
- 18 Geijer M, Göthlin GG, Göthlin JH. The clinical utility of computed tomography compared to conventional radiography in diagnosing sacroiliitis. A retrospective study on 910 patients and literature review. *J Rheumatol* 2007;34:1561–5.
- 19 Bennett AN, McGonagle D, O'Connor P, *et al.* Severity of baseline magnetic resonance imaging-evident sacroiliitis and HLA-B27 status in early inflammatory back pain predict radiographically evident ankylosing spondylitis at eight years. *Arthritis Rheum* 2008;58:3413–18.
- 20 Marzo-Ortega H, McGonagle D, O'Connor P, *et al.* Baseline and 1-year magnetic resonance imaging of the sacroiliac joint and lumbar spine in very early inflammatory back pain. Relationship between symptoms, HLA-B27 and disease extent and persistence. *Ann Rheum Dis* 2009;68:1721–7.
- 21 Oostveen J, Prevo R, den Boer J, *et al.* Early detection of sacroiliitis on magnetic resonance imaging and subsequent development of sacroiliitis on plain radiography. A prospective, longitudinal study. *J Rheumatol* 1999;26:1953–8.
- 22 Weber U, Lambert RG, Pedersen SJ, *et al.* Assessment of structural lesions in sacroiliac joints enhances diagnostic utility of magnetic resonance imaging in early spondylarthritis. *Arthritis Care Res (Hoboken)* 2010;62:1763–71.
- 23 Weber U, Lambert RG, Østergaard M, *et al.* The diagnostic utility of magnetic resonance imaging in spondylarthritis: an international multicenter evaluation of one hundred eighty-seven subjects. *Arthritis Rheum* 2010;62:3048–58.
- 24 Weber U, Pedersen SJ, Zubler V, *et al.* What constitutes the characteristic fat lesion on MRI of the sacroiliac joints in early spondyloarthritis? *Arthritis Rheum* 2012;64 (Suppl 10):1024.
- 25 Weber U, Zubler V, Pedersen SJ, *et al.* Development and validation of a magnetic resonance imaging reference criterion for defining a positive sacroiliac joint magnetic resonance imaging finding in spondyloarthritis. *Arthritis Care Res Hoboken* 2013;65:977–85.
- 26 Wick MC, Weiss RJ, Jaschke W, *et al.* Erosions are the most relevant magnetic resonance imaging features in quantification of sacroiliac joints in ankylosing spondylitis. *J Rheumatol* 2010;37:622–7.
- 27 Heuft-Dorenbosch L, Landewé R, Weijers R, *et al.* Combining information obtained from magnetic resonance imaging and conventional radiographs to detect sacroiliitis in patients with recent onset inflammatory back pain. *Ann Rheum Dis* 2006;65:804–8.
- 28 Bennett AN, Rehman A, Hensor EM, *et al.* Evaluation of the diagnostic utility of spinal magnetic resonance imaging in axial spondylarthritis. *Arthritis Rheum* 2009;60:1331–41.
- 29 Bennett AN, Rehman A, Hensor EM, *et al.* The fatty Romanus lesion: a non-inflammatory spinal MRI lesion specific for axial spondyloarthritis. *Ann Rheum Dis* 2010;69:891–4.
- 30 Weber U, Hodler J, Kubik RA, *et al.* Sensitivity and specificity of spinal inflammatory lesions assessed by whole-body magnetic resonance imaging in patients with ankylosing spondylitis or recent-onset inflammatory back pain. *Arthritis Rheum* 2009;61:900–8.
- 31 Kim NR, Choi JY, Hong SH, *et al.* "MR corner sign": value for predicting presence of ankylosing spondylitis. *AJR Am J Roentgenol* 2008;191:124–8.
- 32 Weber U, Zubler V, Zhao Z, *et al.* Does spinal MRI add incremental diagnostic value to MRI of the sacroiliac joints alone in patients with non-radiographic axial spondyloarthritis? *Ann Rheum Dis* 2015;74:985–92.
- 33 Inanc N, Atagündüz P, Sen F, *et al.* The investigation of sacroiliitis with different imaging techniques in spondyloarthropathies. *Rheumatol Int* 2005;25:591–4.
- 34 Chase WF, Houk RW, Winn RE, *et al.* The clinical usefulness of radionuclide scintigraphy in suspected sacro-iliitis: a prospective study. *Br J Rheumatol* 1983;22:67–72.
- 35 Song IH, Brandt H, Rudwaleit M, *et al.* Limited diagnostic value of unilateral sacroiliitis in scintigraphy in assessing axial spondyloarthritis. *J Rheumatol* 2010;37:1200–2.
- 36 Klausner A, Halpern EJ, Ferauscher F, *et al.* Inflammatory low back pain: high negative predictive value of contrast-enhanced color Doppler ultrasound in the detection of inflamed sacroiliac joints. *Arthritis Rheum* 2005;53:440–4.
- 37 Klausner AS, De Zordo T, Bellmann-Weiler R, *et al.* Feasibility of second-generation ultrasound contrast media in the detection of active sacroiliitis. *Arthritis Rheum* 2009;61:909–16.
- 38 Mohammadi A, Ghasemi-rad M, Aghdashi M, *et al.* Evaluation of disease activity in ankylosing spondylitis: diagnostic value of color Doppler ultrasonography. *Skeletal Radiol* 2013;42:219–24.
- 39 Aydin SZ, Ash ZR, Tinazzi I, *et al.* The link between enthesitis and arthritis in psoriatic arthritis: a switch to a vascular phenotype at insertions may play a role in arthritis development. *Ann Rheum Dis* 2013;72:992–5.
- 40 D'Agostino MA, Said-Nahal R, Hacquard-Bouder C, *et al.* Assessment of peripheral enthesitis in the spondylarthropathies by ultrasonography combined with power Doppler: a cross-sectional study. *Arthritis Rheum* 2003;48:523–33.
- 41 D'Agostino MA, Aegerter P, Bechara K, *et al.* How to diagnose spondyloarthritis early? Accuracy of peripheral enthesitis detection by power Doppler ultrasonography. *Ann Rheum Dis* 2011;70:1433–40.
- 42 de Miguel E, Cobo T, Muñoz-Fernández S, *et al.* Validity of enthesitis ultrasound assessment in spondyloarthropathy. *Ann Rheum Dis* 2009;68:169–74.
- 43 de Miguel E, Muñoz-Fernández S, Castillo C, *et al.* Diagnostic accuracy of enthesitis ultrasound in the diagnosis of early spondyloarthritis. *Ann Rheum Dis* 2011;70:434–9.
- 44 Feydy A, Lavie-Brion MC, Gossec L, *et al.* Comparative study of MRI and power Doppler ultrasonography of the heel in patients with spondyloarthritis with and without heel pain and in controls. *Ann Rheum Dis* 2012;71:498–503.
- 45 Ibrahim G, Groves C, Chandramohan M, *et al.* Clinical and ultrasound examination of the leads enthesitis index in psoriatic arthritis and rheumatoid arthritis. *ISRN Rheumatol* 2011;2011:731917.
- 46 Marchesoni A, De Lucia O, Rotunno L, *et al.* Enthesal power Doppler ultrasonography: a comparison of psoriatic arthritis and fibromyalgia. *J Rheumatol* 2012;89:29–31.
- 47 Farouk HM, Mostafa AA, Youssef SS, *et al.* Value of enthesal ultrasonography and serum cartilage oligomeric matrix protein in the preclinical diagnosis of psoriatic arthritis. *Clin Med Insights Arthritis Musculoskelet Disord* 2010;3:7–14.
- 48 Althoff CE, Feist E, Burova E, *et al.* Magnetic resonance imaging of active sacroiliitis: do we really need gadolinium? *Eur J Radiol* 2009;71:232–6.
- 49 Baraliakos X, Hermann KG, Landewé R, *et al.* Assessment of acute spinal inflammation in patients with ankylosing spondylitis by magnetic resonance imaging: a comparison between contrast enhanced T1 and short tau inversion recovery (STIR) sequences. *Ann Rheum Dis* 2005;64:1141–4.
- 50 Baraliakos X, Davis J, Tsuji W, *et al.* Magnetic resonance imaging examinations of the spine in patients with ankylosing spondylitis before and after therapy with the tumor necrosis factor alpha receptor fusion protein etanercept. *Arthritis Rheum* 2005;52:1216–23.
- 51 Blachier M, Coutanceau B, Dougados M, *et al.* Does the site of magnetic resonance imaging abnormalities match the site of recent-onset inflammatory back pain? The DESIR cohort. *Ann Rheum Dis* 2013;72:979–85.
- 52 Bonel HM, Boller C, Saar B, *et al.* Short-term changes in magnetic resonance imaging and disease activity in response to infliximab. *Ann Rheum Dis* 2010;69:120–5.
- 53 Braun J, Baraliakos X, Golder W, *et al.* Magnetic resonance imaging examinations of the spine in patients with ankylosing spondylitis, before and after successful therapy with infliximab: evaluation of a new scoring system. *Arthritis Rheum* 2003;48:1126–36.
- 54 Braun J, Baraliakos X, Hermann KG, *et al.* Golimumab reduces spinal inflammation in ankylosing spondylitis: MRI results of the randomised, placebo- controlled GO-RAISE study. *Ann Rheum Dis* 2012;71:878–84.
- 55 Goh L, Suresh P, Gafoor A, *et al.* Disease activity in longstanding ankylosing spondylitis: a correlation of clinical and magnetic resonance imaging findings. *Clin Rheumatol* 2008;27:449–55.
- 56 de Hooge M, van den Berg R, Navarro-Compán V, *et al.* Magnetic resonance imaging of the sacroiliac joints in the early detection of spondyloarthritis: no added value of gadolinium compared with short tau inversion recovery sequence. *Rheumatology (Oxford)* 2013;52:1220–4.
- 57 Hermann KG, Landewé RB, Braun J, *et al.* Magnetic resonance imaging of inflammatory lesions in the spine in ankylosing spondylitis clinical trials: is paramagnetic contrast medium necessary? *J Rheumatol* 2005;32:2056–60.
- 58 Hu Z, Xu M, Li Q, *et al.* Adalimumab significantly reduces inflammation and serum DKK-1 level but increases fatty deposition in lumbar spine in active ankylosing spondylitis. *Int J Rheum Dis* 2012;15:358–65.
- 59 Kiltz U, Baraliakos X, Karakostas P, *et al.* The degree of spinal inflammation is similar in patients with axial spondyloarthritis who report high or low levels of disease activity: a cohort study. *Ann Rheum Dis* 2012;71:1207–11.
- 60 Konca S, Keskin D, Ciliz D, *et al.* Spinal inflammation by magnetic resonance imaging in patients with ankylosing spondylitis: association with disease activity and outcome parameters. *Rheumatol Int* 2012;32:3765–70.
- 61 Lambert RG, Salonen D, Rahman P, *et al.* Adalimumab significantly reduces both spinal and sacroiliac joint inflammation in patients with ankylosing spondylitis: a multicenter, randomized, double-blind, placebo-controlled study. *Arthritis Rheum* 2007;56:4005–14.
- 62 Lukas C, Braun J, van der Heijde D, *et al.* Scoring inflammatory activity of the spine by magnetic resonance imaging in ankylosing spondylitis: a multireader experiment. *J Rheumatol* 2007;34:862–70.
- 63 Machado P, Landewé R, Braun J, *et al.* A stratified model for health outcomes in ankylosing spondylitis. *Ann Rheum Dis* 2011;70:1758–64.
- 64 Machado P, Landewé RB, Braun J, *et al.* MRI inflammation and its relation with measures of clinical disease activity and different treatment responses in patients with ankylosing spondylitis treated with a tumour necrosis factor inhibitor. *Ann Rheum Dis* 2012;71:2002–5.
- 65 Madsen KB, Egund N, Jurik AG. Grading of inflammatory disease activity in the sacroiliac joints with magnetic resonance imaging: comparison between short-tau

- inversion recovery and gadolinium contrast-enhanced sequences. *J Rheumatol* 2010;37:393–400.
- 66 Maksymowych WP, Dhillon SS, Park R, *et al.* Validation of the spondyloarthritis research consortium of Canada magnetic resonance imaging spinal inflammation index: is it necessary to score the entire spine? *Arthritis Rheum* 2007;57:501–7.
- 67 Maksymowych WP, Salonen D, Inman RD, *et al.* Low-dose infliximab (3 mg/kg) significantly reduces spinal inflammation on magnetic resonance imaging in patients with ankylosing spondylitis: a randomized placebo-controlled study. *J Rheumatol* 2010;37:1728–34.
- 68 Marzo-Ortega H, McGonagle D, Jarrett S, *et al.* Infliximab in combination with methotrexate in active ankylosing spondylitis: a clinical and imaging study. *Ann Rheum Dis* 2005;64:1568–75.
- 69 Pedersen SJ, Sørensen IJ, Hermann KG, *et al.* Responsiveness of the Ankylosing Spondylitis Disease Activity Score (ASDAS) and clinical and MRI measures of disease activity in a 1-year follow-up study of patients with axial spondyloarthritis treated with tumour necrosis factor alpha inhibitors. *Ann Rheum Dis* 2010;69:1065–71.
- 70 Puhakka KB, Jurik AG, Schiøtz-Christensen B, *et al.* Magnetic resonance imaging of sacroiliitis in early seronegative spondylarthropathy. Abnormalities correlated to clinical and laboratory findings. *Rheumatology (Oxford)* 2004;43:234–7.
- 71 Puhakka KB, Jurik AG, Schiøtz-Christensen B, *et al.* MRI abnormalities of sacroiliac joints in early spondylarthropathy: a 1-year follow-up study. *Scand J Rheumatol* 2004;33:332–8.
- 72 Rudwaleit M, Baraliakos X, Listing J, *et al.* Magnetic resonance imaging of the spine and the sacroiliac joints in ankylosing spondylitis and undifferentiated spondyloarthritis during treatment with etanercept. *Ann Rheum Dis* 2005;64:1305–10.
- 73 Rudwaleit M, Schwarzlose S, Hilgert ES, *et al.* MRI in predicting a major clinical response to anti-tumour necrosis factor treatment in ankylosing spondylitis. *Ann Rheum Dis* 2008;67:1276–81.
- 74 Sieper J, Baraliakos X, Listing J, *et al.* Persistent reduction of spinal inflammation as assessed by magnetic resonance imaging in patients with ankylosing spondylitis after 2 yrs of treatment with the anti-tumour necrosis factor agent infliximab. *Rheumatology (Oxford)* 2005;44:1525–30.
- 75 Sieper J, van der Heijde D, Dougados M, *et al.* Efficacy and safety of adalimumab in patients with non-radiographic axial spondyloarthritis: results of a randomised placebo-controlled trial (ABILITY-1). *Ann Rheum Dis* 2013;72:815–22.
- 76 Song IH, Hermann K, Haibel H, *et al.* Effects of etanercept versus sulfasalazine in early axial spondyloarthritis on active inflammatory lesions as detected by whole-body MRI (ESTHER): a 48-week randomised controlled trial. *Ann Rheum Dis* 2011;70:590–6.
- 77 Visvanathan S, Wagner C, Marini JC, *et al.* Inflammatory biomarkers, disease activity and spinal disease measures in patients with ankylosing spondylitis after treatment with infliximab. *Ann Rheum Dis* 2008;67:511–17.
- 78 Weber U, Maksymowych WP, Jurik AG. Validation of whole-body against conventional magnetic resonance imaging for scoring acute inflammatory lesions in the sacroiliac joints of patients with spondylarthritis. *Arthritis Rheum* 2009;61:893–9.
- 79 Weber U, Lambert RG, Rufibach K, *et al.* Anterior chest wall inflammation by whole-body magnetic resonance imaging in patients with spondyloarthritis: lack of association between clinical and imaging findings in a cross-sectional study. *Arthritis Res Ther* 2012;14:R3.
- 80 Akgul O, Gulkesen A, Akgol G, *et al.* MR-defined fat infiltration of the lumbar paravertebral muscles differs between non-radiographic axial spondyloarthritis and established ankylosing spondylitis. *Mod Rheumatol* 2013;23:811–16.
- 81 Avers HL, Oxtoby J, Taylor HG, *et al.* Radiological outcome in ankylosing spondylitis: use of the Stoke Ankylosing Spondylitis Spine Score (SASSS). *Br J Rheumatol* 1996;35:373–6.
- 82 Baraliakos X, Listing J, Rudwaleit M, *et al.* Radiographic progression in patients with ankylosing spondylitis after 2 years of treatment with the tumour necrosis factor alpha antibody infliximab. *Ann Rheum Dis* 2005;64:1462–6.
- 83 Baraliakos X, Listing J, Rudwaleit M, *et al.* Development of a radiographic scoring tool for ankylosing spondylitis only based on bone formation: addition of the thoracic spine improves sensitivity to change. *Arthritis Rheum* 2009;61:764–71.
- 84 Braun J, Baraliakos X, Golder W, *et al.* Analysing chronic spinal changes in ankylosing spondylitis: a systematic comparison of conventional X rays with magnetic resonance imaging using established and new scoring systems. *Ann Rheum Dis* 2004;63:1046–55.
- 85 Creemers MC, Franssen MJ, van't Hof MA, *et al.* Assessment of outcome in ankylosing spondylitis: an extended radiographic scoring system. *Ann Rheum Dis* 2005;64:127–9.
- 86 Lee JY, Kim JI, Park JY, *et al.* Cervical spine involvement in longstanding ankylosing spondylitis. *Clin Exp Rheumatol* 2005;23:331–8.
- 87 Lubrano E, Marchesoni A, Olivieri I, *et al.* The radiological assessment of axial involvement in psoriatic arthritis: a validation study of the BASRI total and the modified SASSS scoring methods. *Clin Exp Rheumatol* 2009;27:977–80.
- 88 Machado P, Landewe R, Braun J, *et al.* In ankylosing spondylitis, a decrease in MRI spinal inflammation predicts improvement in spinal mobility independently of patient reported symptomatic improvement. *Arthritis Rheum* 2012;64(Suppl 10):563.
- 89 Madsen KB, Jurik AG. Magnetic resonance imaging grading system for active and chronic spondylarthritis changes in the sacroiliac joint. *Arthritis Care Res (Hoboken)* 2010;62:11–18.
- 90 Madsen KB, Jurik AG. MRI grading method for active and chronic spinal changes in spondyloarthritis. *Clin Radiol* 2010;65:6–14.
- 91 Puhakka KB, Jurik AG, Egund N, *et al.* Imaging of sacroiliitis in early seronegative spondylarthropathy. Assessment of abnormalities by MR in comparison with radiography and CT. *Acta Radiol* 2003;44:218–29.
- 92 Ramiro S, van Tubergen A, Stolwijk C, *et al.* Scoring radiographic progression in ankylosing spondylitis: should we use the modified Stoke Ankylosing Spondylitis Spine Score (mSASSS) or the Radiographic Ankylosing Spondylitis Spine Score (RASSS)? *Arthritis Res Ther* 2013;15:R14.
- 93 Salaffi F, Carotti M, Garofalo G, *et al.* Radiological scoring methods for ankylosing spondylitis: a comparison between the Bath Ankylosing Spondylitis Radiology Index and the modified Stoke Ankylosing Spondylitis Spine Score. *Clin Exp Rheumatol* 2007;25:67–74.
- 94 Taylor HG, Wardle T, Beswick EJ, *et al.* The relationship of clinical and laboratory measurements to radiological change in ankylosing spondylitis. *Br J Rheumatol* 1991;30:330–5.
- 95 Taylor HG, Gadd R, Beswick EJ, *et al.* Quantitative radio-isotope scanning in ankylosing spondylitis: a clinical, laboratory and computerised tomographic study. *Scand J Rheumatol* 1991;20:274–9.
- 96 Wanders AJ, Landewé RB, Spoorenberg A, *et al.* What is the most appropriate radiologic scoring method for ankylosing spondylitis? A comparison of the available methods based on the Outcome Measures in Rheumatology Clinical Trials filter. *Arthritis Rheum* 2004;50:2622–32.
- 97 Williamson L, Dockerty JL, Dalbeth N, *et al.* Clinical assessment of sacroiliitis and HLA-B27 are poor predictors of sacroiliitis diagnosed by magnetic resonance imaging in psoriatic arthritis. *Rheumatology (Oxford)* 2004;43:85–8.
- 98 Naredo E, Batlle-Gualda E, García-Vivar ML, *et al.* Power Doppler ultrasonography assessment of entheses in spondyloarthropathies: response to therapy of enthesal abnormalities. *J Rheumatol* 2010;37:2110–17.
- 99 Hamdi W, Chelli-Bouaziz M, Ahmed MS, *et al.* Correlations among clinical, radiographic, and sonographic scores for enthesitis in ankylosing spondylitis. *Joint Bone Spine* 2011;78:270–4.
- 100 Aydin SZ, Karadag O, Filippucci E, *et al.* Monitoring Achilles enthesitis in ankylosing spondylitis during TNF-alpha antagonist therapy: an ultrasound study. *Rheumatology (Oxford)* 2010;49:578–82.
- 101 Borman P, Kopal S, Babaoğlu S, *et al.* Ultrasound detection of enthesal insertions in the foot of patients with spondyloarthropathy. *Clin Rheumatol* 2006;25:373–7.
- 102 Kiris A, Kaya A, Ozgocmen S, *et al.* Assessment of enthesitis in ankylosing spondylitis by power Doppler ultrasonography. *Skeletal Radiol* 2006;35:522–8.
- 103 Balint PV, Kane D, Wilson H, *et al.* Ultrasonography of enthesal insertions in the lower limb in spondyloarthropathy. *Ann Rheum Dis* 2002;61:905–10.
- 104 Milosavljevic J, Lindqvist U, Elvin A. Ultrasound and power Doppler evaluation of the hand and wrist in patients with psoriatic arthritis. *Acta Radiol* 2005;46:374–85.
- 105 Spadaro A, Iagnocco A, Perrotta FM, *et al.* Clinical and ultrasonography assessment of peripheral enthesitis in ankylosing spondylitis. *Rheumatology (Oxford)* 2011;50:2080–6.
- 106 McQueen F, Lassere M, Duer-Jensen A, *et al.* Testing an OMERACT MRI scoring system for peripheral psoriatic arthritis in cross-sectional and longitudinal settings. *J Rheumatol* 2009;36:1811–15.
- 107 Mease P, Genovese MC, Gladstein G, *et al.* Abatacept in the treatment of patients with psoriatic arthritis: results of a six-month, multicenter, randomized, double-blind, placebo-controlled, phase II trial. *Arthritis Rheum* 2011;63:939–48.
- 108 Poggenborg RP, Boyesen P, Wiell C, *et al.* Reduction in MRI inflammation during adalimumab therapy in patients with psoriatic arthritis implementation of the OMERACT PsAMRIS scoring method in a follow-up study. *Arthritis Rheum* 2011;63(Suppl 10):953.
- 109 Bennett AN, Marzo-Ortega H, Tan AL, *et al.* Ten-year follow-up of SpA-related oligoarthritis involving the knee: the presence of psoriasis but not HLA-B27 or baseline MRI bone oedema predicts outcome. *Rheumatology (Oxford)* 2012;51:1099–106.
- 110 Tan YM, Østergaard M, Doyle A, *et al.* MRI bone oedema scores are higher in the arthritis mutilans form of psoriatic arthritis and correlate with high radiographic scores for joint damage. *Arthritis Res Ther* 2009;11:R2.
- 111 Blackmore MG, Gladman DD, Husted J, *et al.* Measuring health status in psoriatic arthritis: the Health Assessment Questionnaire and its modification. *J Rheumatol* 1995;22:886–93.
- 112 Könönen M, Kovero O, Wenneberg B, *et al.* Radiographic signs in the temporomandibular joint in Reiter's disease. *J Orofac Pain* 2002;16:143–7.
- 113 Rahman P, Gladman DD, Cook RJ, *et al.* Radiological assessment in psoriatic arthritis. *Br J Rheumatol* 1998;37:760–5.

- 114 Ravindran J, Cavill C, Balakrishnan C, *et al.* A modified Sharp score demonstrates disease progression in established psoriatic arthritis. *Arthritis Care Res (Hoboken)* 2010;62:86–91.
- 115 Taccari E, Spadaro A, Rinaldi T, *et al.* Comparison of the Health Assessment Questionnaire and Arthritis Impact Measurement Scale in patients with psoriatic arthritis. *Rev Rhum Engl Ed* 1998;65:751–8.
- 116 Baraliakos X, Listing J, Rudwaleit M, *et al.* Progression of radiographic damage in patients with ankylosing spondylitis: defining the central role of syndesmophytes. *Ann Rheum Dis* 2007;66:910–15.
- 117 Baraliakos X, Listing J, Rudwaleit M, *et al.* The relationship between inflammation and new bone formation in patients with ankylosing spondylitis. *Arthritis Res Ther* 2008;10:R104.
- 118 Baraliakos X, Listing J, von der Recke A, *et al.* The natural course of radiographic progression in ankylosing spondylitis-evidence for major individual variations in a large proportion of patients. *J Rheumatol* 2009;36:997–1002.
- 119 Baraliakos X, Heldmann F, Listing J, *et al.* The relationship of inflammation, fatty degeneration and the effect of long-term TNF-blocker treatment on the development of new bone formation in patients with ankylosing spondylitis. *Arthritis Rheum* 2012;64(Suppl 10):780.
- 120 Chiochanwisawakit P, Lambert RG, Conner-Spady B, *et al.* Focal fat lesions at vertebral corners on magnetic resonance imaging predict the development of new syndesmophytes in ankylosing spondylitis. *Arthritis Rheum* 2011;63:2215–25.
- 121 Madsen KB, Schiøttz-Christensen B, Jurik AG. Prognostic significance of magnetic resonance imaging changes of the sacroiliac joints in spondyloarthritis-a followup study. *J Rheumatol* 2010;37:1718–27.
- 122 Maksymowych WP, Landewé R, Conner-Spady B, *et al.* Serum matrix metalloproteinase 3 is an independent predictor of structural damage progression in patients with ankylosing spondylitis. *Arthritis Rheum* 2007;56:1846–53.
- 123 Maksymowych WP, Chiochanwisawakit P, Clare T, *et al.* Inflammatory lesions of the spine on magnetic resonance imaging predict the development of new syndesmophytes in ankylosing spondylitis: evidence of a relationship between inflammation and new bone formation. *Arthritis Rheum* 2009;60:93–102.
- 124 Pedersen SJ, Chiochanwisawakit P, Lambert RG, *et al.* Resolution of inflammation following treatment of ankylosing spondylitis is associated with new bone formation. *J Rheumatol* 2011;38:1349–54.
- 125 Pedersen SJ, Sørensen IJ, Lambert RG, *et al.* Radiographic progression is associated with resolution of systemic inflammation in patients with axial spondylarthritis treated with tumor necrosis factor  $\alpha$  inhibitors: a study of radiographic progression, inflammation on magnetic resonance imaging, and circulating biomarkers of inflammation, angiogenesis, and cartilage and bone turnover. *Arthritis Rheum* 2011;63:3789–800.
- 126 Poddubnyy D, Haibel H, Listing J, *et al.* Baseline radiographic damage, elevated acute-phase reactant levels, and cigarette smoking status predict spinal radiographic progression in early axial spondylarthritis. *Arthritis Rheum* 2012;64:1388–98.
- 127 Song IH, Hermann KG, Haibel H, *et al.* Relationship between active inflammatory lesions in the spine and sacroiliac joints and new development of chronic lesions on whole-body MRI in early axial spondyloarthritis: results of the ESTHER trial at week 48. *Ann Rheum Dis* 2011;70:1257–63.
- 128 van der Heijde D, Machado P, Braun J, *et al.* MRI inflammation at the vertebral unit only marginally predicts new syndesmophyte formation: a multilevel analysis in patients with ankylosing spondylitis. *Ann Rheum Dis* 2012;71:369–73.
- 129 van Tubergen A, Ramiro S, van der Heijde D, *et al.* Development of new syndesmophytes and bridges in ankylosing spondylitis and their predictors: a longitudinal study. *Ann Rheum Dis* 2012;71:518–23.
- 130 Barkham N, Keen HI, Coates LC, *et al.* Clinical and imaging efficacy of infliximab in HLA-B27-Positive patients with magnetic resonance imaging-determined early sacroiliitis. *Arthritis Rheum* 2009;60:946–54.
- 131 Nakstad PH, Server A, Josefsen R. Traumatic cervical injuries in ankylosing spondylitis. *Acta Radiol* 2004;45:222–6.
- 132 Katzberg RW, Benedetti PF, Drake CM, *et al.* Acute cervical spine injuries: prospective MR imaging assessment at a level 1 trauma center. *Radiology* 1999;213:203–12.
- 133 Jansen TL, Aarts MH, Zanen S, *et al.* Risk assessment for osteoporosis by quantitative ultrasound of the heel in ankylosing spondylitis. *Clin Exp Rheumatol* 2003;21:599–604.
- 134 Frediani B, Allegri A, Falsetti P, *et al.* Bone mineral density in patients with psoriatic arthritis. *J Rheumatol* 2001;28:138–43.
- 135 Speden DJ, Calin AI, Ring FJ, *et al.* Bone mineral density, calcaneal ultrasound, and bone turnover markers in women with ankylosing spondylitis. *J Rheumatol* 2002;29:516–21.
- 136 Toussirot E, Michel F, Wendling D. Bone density, ultrasound measurements and body composition in early ankylosing spondylitis. *Rheumatology (Oxford)* 2001;40:882–8.
- 137 Devogelaer JP, Maldague B, Malghem J, *et al.* Appendicular and vertebral bone mass in ankylosing spondylitis. A comparison of plain radiographs with single- and dual-photon absorptiometry and with quantitative computed tomography. *Arthritis Rheum* 2002;35:1062–7.
- 138 Karberg K, Zochling J, Sieper J, *et al.* Bone loss is detected more frequently in patients with ankylosing spondylitis with syndesmophytes. *J Rheumatol* 2005;32:1290–8.
- 139 Altindag O, Karakoc M, Soran N, *et al.* Bone mineral density in patients with ankylosing spondylitis. *Romatizma* 2008;23:42–5.
- 140 Jun JB, Joo KB, Her MY, *et al.* Femoral bone mineral density is associated with vertebral fractures in patients with ankylosing spondylitis: a cross-sectional study. *J Rheumatol* 2006;33:1637–41.
- 141 Meirelles ES, Borelli A, Camargo OP. Influence of disease activity and chronicity on ankylosing spondylitis bone mass loss. *Clin Rheumatol* 1999;18:364–8.
- 142 Mullaji AB, Upadhyay SS, Ho EK. Bone mineral density in ankylosing spondylitis. DEXA comparison of control subjects with mild and advanced cases. *J Bone Joint Surg Br* 1994;76:660–5.
- 143 Will R, Palmer R, Bhalla AK, *et al.* Osteoporosis in early ankylosing spondylitis: a primary pathological event? *Lancet* 1989;2:1483–5.
- 144 Franck H, Meurer T, Hofbauer LC. Evaluation of bone mineral density, hormones, biochemical markers of bone metabolism, and osteoprotegerin serum levels in patients with ankylosing spondylitis. *J Rheumatol* 2004;31:2236–41.
- 145 Gilgil E, Kaçar C, Tuncer T, *et al.* The association of syndesmophytes with vertebral bone mineral density in patients with ankylosing spondylitis. *J Rheumatol* 2005;32:292–4.
- 146 Mermerci Başkan B, Pekin Doğan Y, Sivas F, *et al.* The relation between osteoporosis and vitamin D levels and disease activity in ankylosing spondylitis. *Rheumatol Int* 2010;30:375–81.
- 147 Muntean L, Rojas-Vargas M, Font P, *et al.* Relative value of the lumbar spine and hip bone mineral density and bone turnover markers in men with ankylosing spondylitis. *Clin Rheumatol* 2011;30:691–5.
- 148 Taylan A, Sari I, Akinçi B, *et al.* Biomarkers and cytokines of bone turnover: extensive evaluation in a cohort of patients with ankylosing spondylitis. *BMC Musculoskelet Disord* 2012;13:191.
- 149 Ulu MA, Çevik R, Dilek B. Comparison of PA spine, lateral spine, and femoral BMD measurements to determine bone loss in ankylosing spondylitis. *Rheumatol Int* 2012;29:29.
- 150 Will R, Palmer R, Bhalla AK, *et al.* Bone loss as well as bone formation is a feature of progressive ankylosing spondylitis. *Br J Rheumatol* 1990;29:498–9.
- 151 Vasdev V, Bhakuni D, Garg MK, *et al.* Bone mineral density in young males with ankylosing spondylitis. *Int J Rheum Dis* 2011;14:68–73.
- 152 Korczowska I, Przepiera-Bedzak H, Brzosko M, *et al.* Bone tissue metabolism in men with ankylosing spondylitis. *Adv Med Sci* 2011;56:264–9.
- 153 Sarikaya S, Basaran A, Tekin Y, *et al.* Is osteoporosis generalized or localized to central skeleton in ankylosing spondylitis? *J Clin Rheumatol* 2007;13:20–4.
- 154 Baek HJ, Kang SW, Lee YJ, *et al.* Osteopenia in men with mild and severe ankylosing spondylitis. *Rheumatol Int* 2005;26:30–4.
- 155 Capaci K, Hepguler S, Argin M, *et al.* Bone mineral density in mild and advanced ankylosing spondylitis. *Yonsei Med J* 2003;44:379–84.
- 156 Donnelly S, Doyle DV, Denton A, *et al.* Bone mineral density and vertebral compression fracture rates in ankylosing spondylitis. *Ann Rheum Dis* 1994;53:117–21.
- 157 Klingberg E, Lorentzon M, Mellström D, *et al.* Osteoporosis in ankylosing spondylitis—prevalence, risk factors and methods of assessment. *Arthritis Res Ther* 2012;14:R108.
- 158 Grazio S, Kusić Z, Cvijetić S, *et al.* Relationship of bone mineral density with disease activity and functional ability in patients with ankylosing spondylitis: a cross-sectional study. *Rheumatol Int* 2012;32:2801–8.
- 159 Park MC, Chung SJ, Park YB, *et al.* Bone and cartilage turnover markers, bone mineral density, and radiographic damage in men with ankylosing spondylitis. *Yonsei Med J* 2008;49:288–94.
- 160 van der Weijden MA, van Denderen JC, Lems WF, *et al.* Low bone mineral density is related to male gender and decreased functional capacity in early spondylarthropathies. *Clin Rheumatol* 2011;30:497–503.
- 161 Grisar J, Bernecker PM, Aringer M, *et al.* Ankylosing spondylitis, psoriatic arthritis, and reactive arthritis show increased bone resorption, but differ with regard to bone formation. *J Rheumatol* 2002;29:1430–6.
- 162 Pedreira PG, Pinheiro MM, Szejnfeld VL. Bone mineral density and body composition in postmenopausal women with psoriasis and psoriatic arthritis. *Arthritis Res Ther* 2011;13:R16.
- 163 Dheda K, Cassim B, Patel N, *et al.* A comparison of bone mineral density in Indians with psoriatic polyarthritis and healthy Indian volunteers. *Clin Rheumatol* 2004;23:89.
- 164 Grazio S, Cvijetić S, Vlak T, *et al.* Osteoporosis in psoriatic arthritis: is there any? *Wien Klin Wochenschr* 2011;123:743–50.

- 165 Gratacós J, Collado A, Pons F, *et al.* Significant loss of bone mass in patients with early, active ankylosing spondylitis: a followup study. *Arthritis Rheum* 1999;42:2319–24.
- 166 Haugeberg G, Bennett AN, McGonagle D, *et al.* Bone loss in very early inflammatory back pain in undifferentiated spondyloarthropathy: a 1-year observational study. *Ann Rheum Dis* 2010;69:1364–6.
- 167 Kaya A, Ozgocmen S, Kamanli A, *et al.* Bone loss in ankylosing spondylitis: does syndesmophyte formation have an influence on bone density changes? *Med Princ Pract* 2009;18:470–6.
- 168 Maillefert JF, Aho LS, El Maghraoui A, *et al.* Changes in bone density in patients with ankylosing spondylitis: a two-year follow-up study. *Osteoporos Int* 2001;12:605–9.
- 169 Anandarajah AP, El-Taha M, Peng C, *et al.* Association between focal erosions and generalised bone loss in psoriatic arthritis. *Ann Rheum Dis* 2011;70:1345–7.
- 170 Arends S, Spoorenberg A, Bruyn GA, *et al.* The relation between bone mineral density, bone turnover markers, and vitamin D status in ankylosing spondylitis patients with active disease: a cross-sectional analysis. *Osteoporos Int* 2011;22:1431–9.
- 171 Briot K, Durnez A, Paternotte S, *et al.* Bone oedema on MRI is highly associated with low bone mineral density in patients with early inflammatory back pain: results from the DESIR cohort. *Ann Rheum Dis* 2013;72:1914–19.
- 172 Dos Santos FP, Constantin A, Laroche M, *et al.* Whole body and regional bone mineral density in ankylosing spondylitis. *J Rheumatol* 2001;28:547–9.
- 173 El Maghraoui A, Borderie D, Cherruau B, *et al.* Osteoporosis, body composition, and bone turnover in ankylosing spondylitis. *J Rheumatol* 1999;26:2205–9.
- 174 Mitra D, Elvins DM, Collins AJ. Biochemical markers of bone metabolism in mild ankylosing spondylitis and their relationship with bone mineral density and vertebral fractures. *J Rheumatol* 1999;26:2201–4.
- 175 Lange U, Kluge A, Strunk J, *et al.* Ankylosing spondylitis and bone mineral density—what is the ideal tool for measurement? *Rheumatol Int* 2005;26:115–20.
- 176 Schueller-Weidekamm C, Mascarenhas VV, Sudol-Szopinska I, *et al.* Imaging and interpretation of axial spondylarthritis: the radiologist’s perspective—consensus of the Arthritis Subcommittee of the ESSR. *Semin Musculoskelet Radiol* 2014;18:265–79.

## **SUPPLEMENTARY MATERIAL**

### **S1. Research questions (RQ)**

#### **Making a diagnosis of spondyloarthritis**

**RQ1-** What is the diagnostic value of individual imaging modalities above clinical examination/criteria for axial SpA?

**RQ2-** What is the diagnostic value of individual imaging modalities above clinical examination/criteria for peripheral SpA (including peripheral psoriatic arthritis)?

#### **Monitoring disease activity and structural damage in spondyloarthritis**

**RQ3-** What is the ability, and added value above other measures (e.g. clinical examination, PROs, CRP, other imaging modalities) of individual imaging modalities to monitor disease activity in axial SpA?

**RQ4-** What is the ability, and added value above other measures (e.g. clinical examination, PROs, CRP, other imaging modalities) of individual imaging modalities to monitor structural changes in axial SpA?

**RQ5-** What is the ability, and added value above other measures (e.g. clinical examination, PROs, CRP, other imaging modalities) of individual imaging modalities to monitor disease activity in peripheral SpA(including peripheral psoriatic arthritis)?

**RQ6-** What is the ability, and added value above other measures (e.g. clinical examination, PROs, CRP, other imaging modalities) of individual imaging modalities to monitor structural changes in peripheral SpA(including peripheral psoriatic arthritis)?

#### **Predicting outcome (severity) and treatment response**

**RQ7-** What is the ability, and added value of individual imaging modalities above other measures (e.g. clinical examination, PROs, CRP, other imaging modalities) to predict outcome (severity) in axial SpA?

**RQ8-** What is the ability and value of individual imaging modalities above other measures (e.g. clinical examination, PROs, CRP, other imaging modalities) to predict treatment response in axial SpA?

**RQ9-** What is the ability, and added value of individual imaging modalities above other measures (e.g. clinical examination, PROs, CRP, other imaging modalities) to predict outcome (severity) in peripheral SpA?

**RQ10-** What is the diagnostic value of individual imaging modalities above other measures (e.g. clinical examination, PROs, CRP, other imaging modalities) to predict treatment response in peripheral SpA?

#### **Making a diagnosis of spinal fracture or osteoporosis in spondyloarthritis**

**RQ11-** What is the diagnostic value of individual imaging modalities above other imaging modalities for spinal fractures in SpA?

**RQ12-** What is the ability of individual imaging modalities to diagnose and monitor osteoporosis in SpA?

**S2. Details of search strategy performed using MEDLINE via Pubmed (1948 to January 2013) and EMBASE via Ovid (1980 to January 2013).**

**RQ1-10**

**Search strategy, MEDLINE via Pubmed**

1. "spondylarthropathies"[MeSH Terms]
2. spondylart\*[Text Word]
3. (Reactiv\*[TI] AND Arthriti\*[TI])
4. (Psoria\*[TI] AND Arthriti\*[TI])
5. (ankyl\*[TI] AND Spondyl\*[TI])
6. (((inflam\*[TiAB] AND (peripher\*[TIAB] OR tendon\*[TIAB] or tendinop\*[TIAB] OR limb\*[TIAB]) AND pain [TIAB] )))
7. spondylo\*[TiAB]
8. (((inflam\*[TiAB] AND (back[TIAB] OR spin\*[TIAB]) AND pain [TIAB])))
9. or/1-8
10. "Tomography"[Mesh]
11. "Magnetic Resonance Imaging"[Mesh]
12. "Ultrasonography"[Mesh]
13. "Tomography, X-Ray Computed"[Mesh]
14. "Positron-Emission Tomography and Computed Tomography"[Mesh]
15. "Positron-Emission Tomography"[Mesh]
16. "Tomography, Emission-Computed, Single-Photon"[Mesh]
17. ("magnetic"[All Fields] AND "resonance"[All Fields] AND "imaging"[All Fields])
18. "mri"[All Fields]
19. ultrasono\*[TIAB]
20. echograph\*[TIAB]
21. "CT scan\*"[TIAB]
22. tomograph\*[TIAB]
23. scintigraph\*[TIAB]
24. (PET[Title/Abstract]) AND tomog\*[Title/Abstract]
25. (SPECT[Title/Abstract]) AND photon[Title/Abstract]
26. or/10-25
27. 9 and 26
28. (animals[mh] NOT human[mh])
29. 27 not 28
30. (("case report\*" [TI]) OR (case reports[Publication Type]))
31. 29 not 30
32. english[Language]
33. 31 and 32

## Search strategy, EMBASE via Ovid

1. (magnetic and resonance and imaging).mp.
2. magnetic resonance imaging.mp.
3. mri.mp.
4. Ultrasonography.mp. or exp echography/
5. magnetic resonance imaging.mp. or exp nuclear magnetic resonance imaging/
6. "ultrasono\*".ti,ab.
7. Tomography, X-Ray Computed.mp. or exp computer assisted tomography/
8. "CT scan\*".ti,ab.
9. "echograph\*".ti,ab.
10. "tomograph\*".ti,ab.
11. "scintigraph\*".ti,ab.
12. Positron Emission Tomography.mp. or exp positron emission tomography/
13. (PET and tomog\*).ti,ab.
14. Tomography, Emission-Computed, Single-Photon.mp. or exp single photon emission computer tomography/
15. (SPECT and photon).ti,ab.
16. or/1-15
17. exp ankylosing spondylitis/
18. exp psoriatic arthritis/
19. exp reactive arthritis/
20. exp spondyloarthropathy/
21. (inflam\* and (peripher\* or tendon\* or tendinop\* or limb\*) and pain).ti,ab.
22. "spondylo\*".ti,ab.
23. (inflam\* and (back or spin\*) and pain).ti,ab.
24. or/17-23
25. 16 and 24
26. limit 25 to (conference abstract or conference paper or "conference review" or letter or conference proceeding)
27. 25 not 26
28. limit 27 to (animals or animal studies)
29. limit 28 to human
30. 28 not 29
31. 27 not 30
32. "case report\*".m\_titl.
33. case study.m\_titl.
34. case report/
35. or/28-30
36. 31 not 35
37. limit 36 to english language



## RQ11

### Search strategy, MEDLINE via Pubmed

1. "spondylarthropathies"[MeSH Terms]
2. spondylart\*[Text Word]
3. (Reactiv\*[TI] AND Arthriti\*[TI])
4. (Psoria\*[TI] AND Arthriti\*[TI])
5. (ankyl\*[TI] AND Spondyl\*[TI])
6. (((inflam\*[TiAB] AND (peripher\*[TIAB] OR tendon\*[TIAB] or tendinop\*[TIAB] OR limb\*[TIAB]) AND pain [TIAB] ))))
7. spondylo\*[TiAB]
8. (((inflam\*[TiAB] AND (back[TIAB] OR spin\*[TIAB]) AND pain [TIAB])))
9. or/1-8
10. "Tomography"[Mesh]
11. "Magnetic Resonance Imaging"[Mesh]
12. "Ultrasonography"[Mesh]
13. "Tomography, X-Ray Computed"[Mesh]
14. "Positron-Emission Tomography and Computed Tomography"[Mesh]
15. "Positron-Emission Tomography"[Mesh]
16. "Tomography, Emission-Computed, Single-Photon"[Mesh]
17. ("magnetic"[All Fields] AND "resonance"[All Fields] AND "imaging"[All Fields])
18. "mri"[All Fields]
19. ultrasono\*[TIAB]
20. echograph\*[TIAB]
21. "CT scan\*"[TIAB]
22. tomograph\*[TIAB]
23. scintigraph\*[TIAB]
24. (PET[Title/Abstract]) AND tomog\*[Title/Abstract]
25. (SPECT[Title/Abstract]) AND photon[Title/Abstract]
26. x\*ray\*
27. "Radiography"[Mesh]
28. or/10-27
29. "Fractures, Bone"[Mesh]
30. "Fractures, Spontaneous"[Mesh]
31. "Osteoporotic Fractures"[Mesh]
32. "Spinal Fractures"[Mesh])
33. fractur\*
34. or/29-33
35. 9 and 28 and 34
36. (animals[mh] NOT human[mh])
37. 35 not 36
38. (("case report\*" [TI]) OR (case reports[Publication Type]))
39. 37 not 38
40. english[Language]
41. 39 and 40

## Search strategy, EMBASE via Ovid

1. (magnetic and resonance and imaging).mp.
2. magnetic resonance imaging.mp.
3. mri.mp.
4. Ultrasonography.mp. or exp echography/
5. magnetic resonance imaging.mp. or exp nuclear magnetic resonance imaging/
6. "ultrasono\*".ti,ab.
7. Tomography, X-Ray Computed.mp. or exp computer assisted tomography/
8. "CT scan\*".ti,ab.
9. "echograph\*".ti,ab.
10. "tomograph\*".ti,ab.
11. "scintigraph\*".ti,ab.
12. Positron Emission Tomography.mp. or exp positron emission tomography/
13. (PET and tomog\*).ti,ab.
14. Tomography, Emission-Computed, Single-Photon.mp. or exp single photon emission computer tomography/
15. (SPECT and photon).ti,ab.
16. exp radiography/
17. x\*ray\*.mp.
18. exp X ray/
19. or/1-18
20. exp fracture/
21. fractur\*.mp.
22. or/20-21
23. exp ankylosing spondylitis/
24. exp psoriatic arthritis/
25. exp reactive arthritis/
26. exp spondyloarthropathy/
27. (inflam\* and (peripher\* or tendon\* or tendinop\* or limb\*) and pain).ti,ab.
28. "spondylo\*".ti,ab.
29. (inflam\* and (back or spin\*) and pain).ti,ab.
30. or/23-29
31. 19 and 22 and 30
32. limit 31 to (conference abstract or conference paper or "conference review" or letter or conference proceeding)
33. 31 not 32
34. limit 33 to (animals or animal studies)
35. limit 34 to human
36. 34 not 35
37. 33 not 36
38. "case report\*".m\_titl.
39. case study.m\_titl.
40. case report/
41. or/38-40
42. 37 not 41
43. limit 42 to english language

## RQ12

### Search strategy, MEDLINE via Pubmed

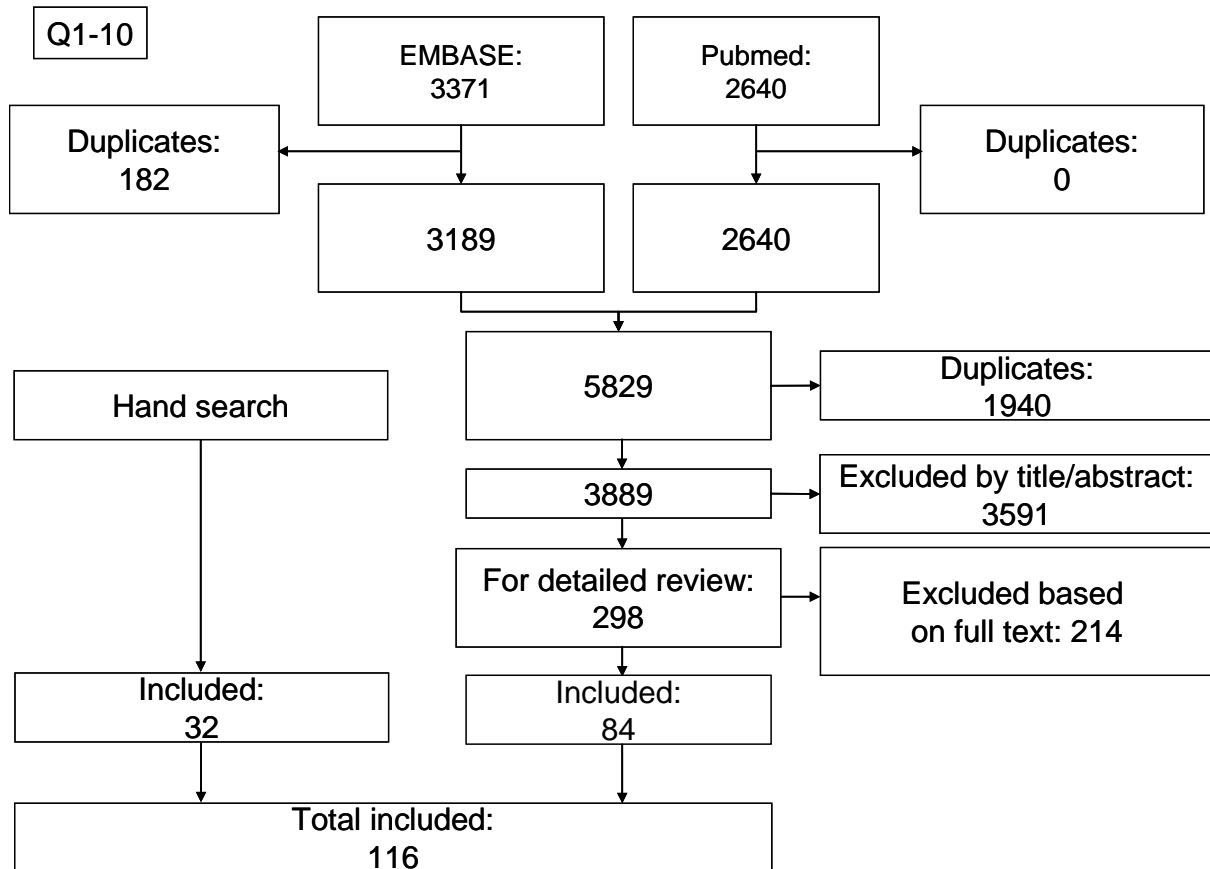
1. "spondylarthropathies"[MeSH Terms]
2. spondylart\*[Text Word]
3. (Reactiv\*[TI] AND Arthriti\*[TI])
4. (Psoria\*[TI] AND Arthriti\*[TI])
5. (ankyl\*[TI] AND Spondyl\*[TI])
6. (((inflam\*[TiAB] AND (peripher\*[TIAB] OR tendon\*[TIAB] or tendinop\*[TIAB] OR limb\*[TIAB]) AND pain [TIAB] ))))
7. spondylo\*[TiAB]
8. (((inflam\*[TiAB] AND (back[TIAB] OR spin\*[TIAB]) AND pain [TIAB])))
9. or/1-8
10. "Tomography"[Mesh]
11. "Magnetic Resonance Imaging"[Mesh]
12. "Ultrasonography"[Mesh]
13. "Tomography, X-Ray Computed"[Mesh]
14. "Positron-Emission Tomography and Computed Tomography"[Mesh]
15. "Positron-Emission Tomography"[Mesh]
16. "Tomography, Emission-Computed, Single-Photon"[Mesh]
17. ("magnetic"[All Fields] AND "resonance"[All Fields] AND "imaging"[All Fields])
18. "mri"[All Fields]
19. ultrasono\*[TIAB]
20. echograph\*[TIAB]
21. "CT scan\*"[TIAB]
22. tomograph\*[TIAB]
23. scintigraph\*[TIAB]
24. (PET[Title/Abstract]) AND tomog\*[Title/Abstract]
25. (SPECT[Title/Abstract]) AND photon[Title/Abstract]
26. x\*ray\*
27. "Radiography"[Mesh]
28. "Absorptiometry, Photon"[Mesh]
29. DEXA
30. (bone\*[TIAB]) AND densit\*[TIAB]
31. "Bone Density"[Mesh]
32. or/10-31
33. osteoporo\*
34. "Osteoporosis"[Mesh]
35. "Bone Density"[Mesh]
36. ((bone\*[TIAB]) AND (loss\*[TIAB] OR densit\*[TIAB] OR mass\*[TIAB]))
37. or/33-36
38. 9 and 32 and 37
39. (animals[mh] NOT human[mh])
40. 38 not 39
41. (("case report\*" [TI]) OR (case reports[Publication Type]))
42. 40 not 41
43. english[Language]
44. 42 and 43

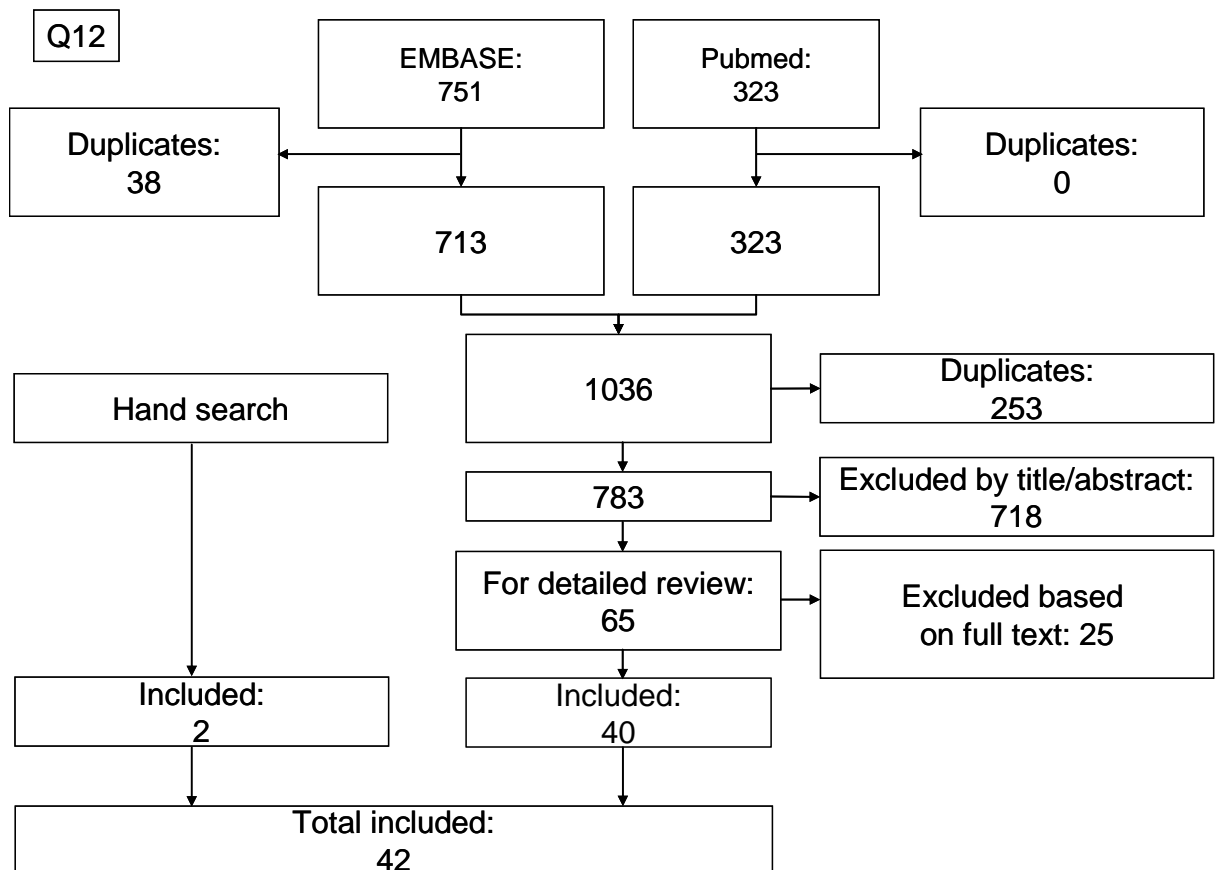
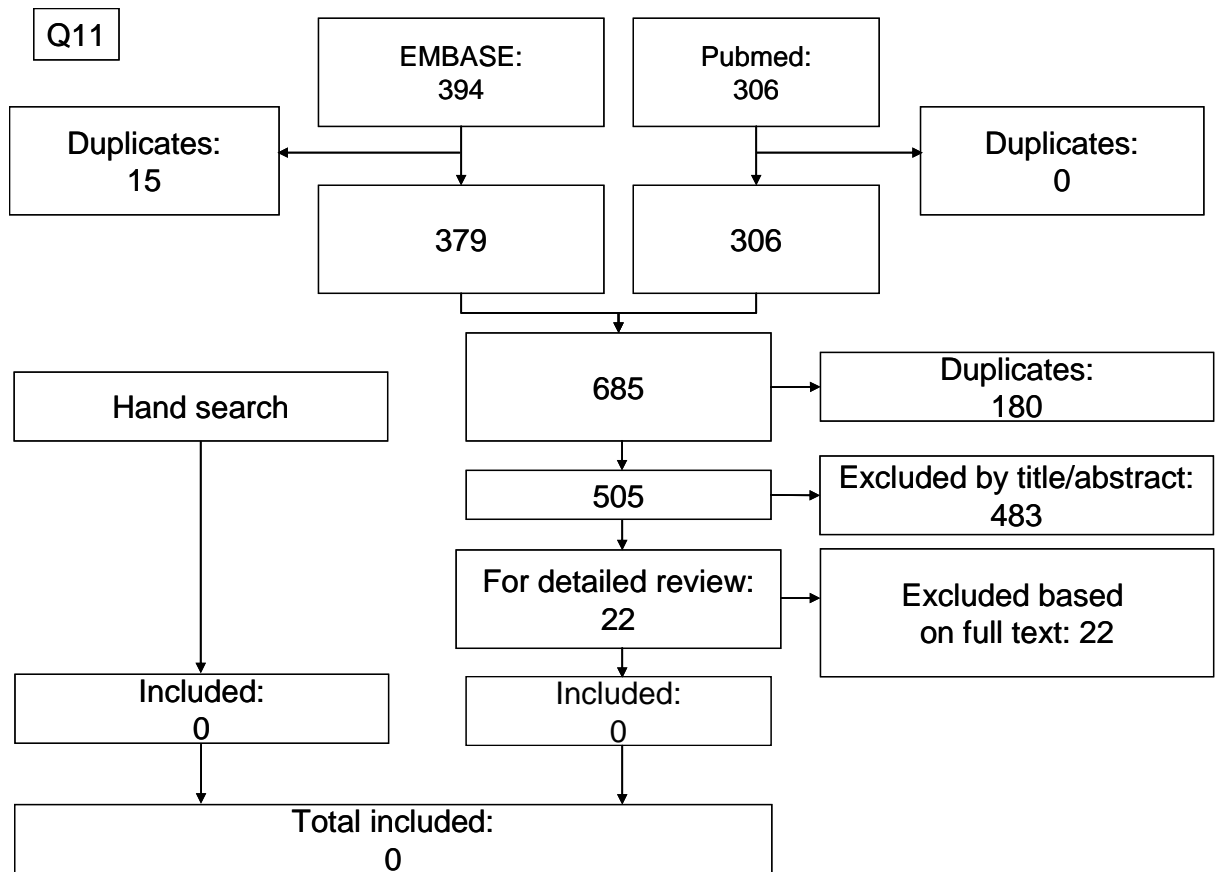
## Search strategy, EMBASE via Ovid

1. (magnetic and resonance and imaging).mp.
2. magnetic resonance imaging.mp.
3. mri.mp.
4. Ultrasonography.mp. or exp echography/
5. magnetic resonance imaging.mp. or exp nuclear magnetic resonance imaging/
6. "ultrasono\*".ti,ab.
7. Tomography, X-Ray Computed.mp. or exp computer assisted tomography/
8. "CT scan\*".ti,ab.
9. "echograph\*".ti,ab.
10. "tomograph\*".ti,ab.
11. "scintigraph\*".ti,ab.
12. Positron Emission Tomography.mp. or exp positron emission tomography/
13. (PET and tomog\*).ti,ab.
14. Tomography, Emission-Computed, Single-Photon.mp. or exp single photon emission computer tomography/
15. (SPECT and photon).ti,ab.
16. exp radiography/
17. x\*ray\*.mp.
18. exp X ray/
19. DEXA.mp. or exp dual energy X ray absorptiometry/
20. exp absorptiometry/ or exp photon absorptiometry/
21. (bone\* and (loss\* or densit\* or mass\*)).ti,ab.
22. Bone Density.mp. or exp bone density/
23. or/1-22
24. (bone\* and (loss\* or densit\* or mass\*)).ti,ab.
25. Bone Density.mp. or exp bone density/
26. exp osteoporosis/ or Osteoporosis.mp.
27. osteoporo\*.mp
28. or/24-27
29. exp ankylosing spondylitis/
30. exp psoriatic arthritis/
31. exp reactive arthritis/
32. exp spondyloarthropathy/
33. (inflam\* and (peripher\* or tendon\* or tendinop\* or limb\*) and pain).ti,ab.
34. "spondylo\*".ti,ab.
35. (inflam\* and (back or spin\*) and pain).ti,ab.
36. or/29-35
37. 23 and 28 and 36
38. limit 37 to (conference abstract or conference paper or "conference review" or letter or conference proceeding)
39. 37 not 38
40. limit 39 to (animals or animal studies)
41. limit 40 to human
42. 40 not 41
43. 39 not 42
44. "case report\*".m\_titl.
45. case study.m\_titl.
46. case report/

- 47. or/44-46
- 48. 43 not 47
- 49. limit 48 to english language

**S3. Flowcharts showing the three separate literature searches of 7550 articles, from which 298 articles were selected for detailed review; 157 articles were included in the final analysis.**





#### S4. Number of included articles per research question

|  | Number of included articles |
|--|-----------------------------|
| <b>RQ1- What is the diagnostic value of individual imaging modalities above clinical examination/criteria for axial SpA?</b>   | <b>25</b>                   |
| <b>RQ2- What is the diagnostic value of individual imaging modalities above clinical examination/criteria for peripheral SpA (including peripheral psoriatic arthritis)?</b>   | <b>9</b>                    |
| <b>RQ3- What is the ability, and added value above other measures (e.g. clinical examination, PROs, CRP, other imaging modalities) of individual imaging modalities to monitor disease activity in axial SpA?</b>  | <b>34</b>                   |
| <b>RQ4- What is the ability, and added value above other measures (e.g. clinical examination, PROs, CRP, other imaging modalities) of individual imaging modalities to monitor structural changes in axial SpA?</b>  | <b>23</b>                   |
| <b>RQ5- What is the ability, and added value above other measures (e.g. clinical examination, PROs, CRP, other imaging modalities) of individual imaging modalities to monitor disease activity in peripheral SpA(including peripheral psoriatic arthritis)?</b>   | <b>15</b>                   |
| <b>RQ6- What is the ability, and added value above other measures (e.g. clinical examination, PROs, CRP, other imaging modalities) of individual imaging modalities to monitor structural changes in peripheral SpA(including peripheral psoriatic arthritis)?</b> | <b>8</b>                    |
| <b>RQ7- What is the ability, and added value of individual imaging modalities above other measures (e.g. clinical examination, PROs, CRP, other imaging modalities) to predict outcome (severity) in axial SpA?</b>  | <b>17</b>                   |
| <b>RQ8- What is the ability and value of individual imaging modalities above other measures (e.g. clinical examination, PROs, CRP, other imaging modalities) to predict treatment response in axial SpA?</b>   | <b>3</b>                    |
| <b>RQ9 - What is the ability, and added value of individual imaging modalities above other measures (e.g. clinical examination, PROs, CRP, other imaging modalities) to predict outcome (severity) in peripheral SpA?</b>  | <b>3</b>                    |
| <b>RQ10- What is the diagnostic value of individual imaging modalities above other measures (e.g. clinical examination, PROs, CRP, other imaging modalities) to predict treatment response in peripheral SpA?</b>  | <b>0</b>                    |
| <b>RQ11 - What is the diagnostic value of individual imaging modalities above other imaging modalities for spinal fractures in SpA?</b>  | <b>0</b>                    |
| <b>RQ12 - What is the ability of individual imaging modalities to diagnose and monitor osteoporosis in SpA?</b>  | <b>42</b>                   |



## **S5. Reference list of included articles per recommendation**

### **Recommendation 1: Diagnosing axial SpA**

**A. In general, conventional radiography of the SI joints is recommended as the first imaging method to diagnose sacroiliitis as part of axial SpA. In certain cases, such as young patients and those with short symptom duration, MRI of the SI joints is an alternative first imaging method.**

**B. If the diagnosis of axial SpA cannot be established based on clinical features and conventional radiography, and axial SpA is still suspected, MRI of the SI joints is recommended. On MRI, both active inflammatory lesions (primarily bone marrow edema) and structural lesions (such as bone erosion, new bone formation, sclerosis and fat infiltration) should be considered. MRI of the spine is not generally recommended to diagnose axial SpA.**

**C. Imaging modalities other than conventional radiography and MRI are not generally recommended in the diagnosis of axial SpA\*.**

**\*CT may provide additional information on structural damage if conventional radiography is negative and MRI cannot be performed. Scintigraphy and US are not recommended for diagnosis of sacroiliitis as part of axial SpA.**

1. Bennett AN, McGonagle D, O'Connor P, et al. Severity of baseline magnetic resonance imaging-evident sacroiliitis and HLA-B27 status in early inflammatory back pain predict radiographically evident ankylosing spondylitis at eight years. *Arthritis Rheum* 2008;58:3413-8.
2. Bennett AN, Rehman A, Hensor EM, et al. Evaluation of the diagnostic utility of spinal magnetic resonance imaging in axial spondylarthritis. *Arthritis Rheum* 2009;60:1331-41.
3. Bennett AN, Rehman A, Hensor EM, et al. The fatty Romanus lesion: a non-inflammatory spinal MRI lesion specific for axial spondyloarthritis. *Ann Rheum Dis* 2010;69:891-4.
4. Blum U, Buitrago-Tellez C, Mundinger A, et al. Magnetic resonance imaging (MRI) for detection of active sacroiliitis--a prospective study comparing conventional radiography, scintigraphy, and contrast enhanced MRI. *J Rheumatol* 1996;23:2107-15.
5. Chase WF, Houk RW, Winn RE, et al. The clinical usefulness of radionuclide scintigraphy in suspected sacro-iliitis: a prospective study. *Br J Rheumatol* 1983;22:67-72.
6. Devauchelle-Pensec V, D'Agostino MA, Marion J, et al. Computed tomography scanning facilitates the diagnosis of sacroiliitis in patients with suspected spondylarthritis: results of a prospective multicenter French cohort study. *Arthritis Rheum* 2012;64:1412-9.
7. Geijer M, Göthlin GG, Göthlin JH. The clinical utility of computed tomography compared to conventional radiography in diagnosing sacroiliitis. A retrospective study on 910 patients and literature review. *J Rheumatol* 2007;34:1561-5.
8. Goie The HS, Steven MM, van der Linden SM, et al. Evaluation of diagnostic criteria for ankylosing spondylitis: a comparison of the Rome, New York and modified New York criteria in patients with a positive clinical history screening test for ankylosing spondylitis. *Br J Rheumatol* 1985;24:242-9.

9. Heuft-Dorenbosch L, Landewé R, Weijers R, et al. Combining information obtained from magnetic resonance imaging and conventional radiographs to detect sacroiliitis in patients with recent onset inflammatory back pain. *Ann Rheum Dis* 2006;65:804-8.
10. Inanc N, Atagündüz P, Sen F, et al. The investigation of sacroiliitis with different imaging techniques in spondyloarthropathies. *Rheumatol Int* 2005;25:591-4.
11. Kim NR, Choi JY, Hong SH, et al. "MR corner sign": value for predicting presence of ankylosing spondylitis. *AJR Am J Roentgenol* 2008;191:124-8.
12. Klauser A, Halpern EJ, Frauscher F, et al. Inflammatory low back pain: high negative predictive value of contrast-enhanced color Doppler ultrasound in the detection of inflamed sacroiliac joints. *Arthritis Rheum* 2005;53:440-4.
13. Klauser AS, De Zordo T, Bellmann-Weiler R, et al. Feasibility of second-generation ultrasound contrast media in the detection of active sacroiliitis. *Arthritis Rheum* 2009;61:909-16.
14. Marzo-Ortega H, McGonagle D, O'Connor P, et al. Baseline and 1-year magnetic resonance imaging of the sacroiliac joint and lumbar spine in very early inflammatory back pain. Relationship between symptoms, HLA-B27 and disease extent and persistence. *Ann Rheum Dis* 2009;68:1721-7.
15. Mohammadi A, Ghasemi-rad M, Aghdashi M, et al. Evaluation of disease activity in ankylosing spondylitis; diagnostic value of color Doppler ultrasonography. *Skeletal Radiol* 2013;42:219-24.
16. Oostveen J, Prevo R, den Boer J, et al. Early detection of sacroiliitis on magnetic resonance imaging and subsequent development of sacroiliitis on plain radiography. A prospective, longitudinal study. *J Rheumatol* 1999;26:1953-8.
17. Song IH, Brandt H, Rudwaleit M, et al. Limited diagnostic value of unilateral sacroiliitis in scintigraphy in assessing axial spondyloarthritis. *J Rheumatol* 2010;37:1200-2.
18. van Tubergen A, Heuft-Dorenbosch L, Schulpen G, et al. Radiographic assessment of sacroiliitis by radiologists and rheumatologists: does training improve quality? *Ann Rheum Dis* 2003;62:519-25.
19. Weber U, Hodler J, Kubik RA, et al. Sensitivity and specificity of spinal inflammatory lesions assessed by whole-body magnetic resonance imaging in patients with ankylosing spondylitis or recent-onset inflammatory back pain. *Arthritis Rheum* 2009;61:900-8.
20. Weber U, Lambert RG, Østergaard M, et al. The diagnostic utility of magnetic resonance imaging in spondylarthritis: an international multicenter evaluation of one hundred eighty-seven subjects. *Arthritis Rheum* 2010;62:3048-58.
21. Weber U, Lambert RG, Pedersen SJ, et al. Assessment of structural lesions in sacroiliac joints enhances diagnostic utility of magnetic resonance imaging in early spondylarthritis. *Arthritis Care Res (Hoboken)* 2010;62:1763-71.

22. Weber U, Pedersen SJ, Zubler V, et al. What constitutes the characteristic fat lesion on MRI of the sacroiliac joints in early spondyloarthritis? *Arthritis Rheum* 2012;64 Suppl 10:1024
23. Weber U, Zubler V, Pedersen SJ, et al. Development and validation of a magnetic resonance imaging reference criterion for defining a positive sacroiliac joint magnetic resonance imaging finding in spondyloarthritis. *Arthritis Care Res Hoboken* 2013;65:977-85.
24. Weber U, Zubler V, Zhao Z, et al. Does spinal MRI add incremental diagnostic value to MRI of the sacroiliac joints alone in patients with non-radiographic axial spondyloarthritis? *Ann Rheum Dis* 2014 Jan 22. [Epub ahead of print]
25. Wick MC, Weiss RJ, Jaschke W, et al. Erosions are the most relevant magnetic resonance imaging features in quantification of sacroiliac joints in ankylosing spondylitis. *J Rheumatol* 2010;37:622-7.

### **Recommendation 2: Diagnosing peripheral SpA**

**When peripheral SpA is suspected, US or MRI may be used to detect peripheral enthesitis, which may support the diagnosis of SpA. Furthermore, US or MRI might be used to detect peripheral arthritis, tenosynovitis and bursitis.**

1. Aydin SZ, Ash ZR, Tinazzi I, et al. The link between enthesitis and arthritis in psoriatic arthritis: a switch to a vascular phenotype at insertions may play a role in arthritis development. *Ann Rheum Dis* 2013;72:992-5.
2. D'Agostino MA, Said-Nahal R, Hacquard-Bouder C, et al. Assessment of peripheral enthesitis in the spondylarthropathies by ultrasonography combined with power Doppler: a cross-sectional study. *Arthritis Rheum* 2003;48:523-33.
3. D'Agostino MA, Aegerter P, Bechara K, et al. How to diagnose spondyloarthritis early? Accuracy of peripheral enthesitis detection by power Doppler ultrasonography. *Ann Rheum Dis* 2011;70:1433-40.
4. de Miguel E, Cobo T, Muñoz-Fernández S, et al. Validity of enthesitis ultrasound assessment in spondyloarthropathy. *Ann Rheum Dis* 2009;68:169-74.
5. de Miguel E, Muñoz-Fernández S, Castillo C, et al. Diagnostic accuracy of enthesitis ultrasound in the diagnosis of early spondyloarthritis. *Ann Rheum Dis* 2011;70:434-9.
6. Farouk HM, Mostafa AA, Youssef SS, et al. Value of enthesal ultrasonography and serum cartilage oligomeric matrix protein in the preclinical diagnosis of psoriatic arthritis. *Clin Med Insights Arthritis Musculoskelet Disord* 2010 29;3:7-14.
7. Feydy A, Lavie-Brion MC, Gossec L, et al. Comparative study of MRI and power Doppler ultrasonography of the heel in patients with spondyloarthritis with and without heel pain and in controls. *Ann Rheum Dis* 2012;71:498-503.
8. Ibrahim G, Groves C, Chandramohan M, et al. Clinical and ultrasound examination of the Leeds enthesitis index in psoriatic arthritis and rheumatoid arthritis. *ISRN Rheumatol* 2011;:731917.

9. Marchesoni A, De Lucia O, Rotunno L, et al. Enthesal power Doppler ultrasonography: a comparison of psoriatic arthritis and fibromyalgia. *J Rheumatol* 2012;89:29-31.

### **Recommendation 3: Monitoring disease activity in axial SpA**

**MRI of the SI-joints and/or the spine may be used to assess and monitor disease activity in axial SpA, providing additional information on top of clinical and biochemical assessments. The decision on when to repeat MRI depends on the clinical circumstances. In general, STIR sequences are sufficient to detect inflammation and the use of contrast medium is not needed.**

1. Althoff CE, Feist E, Burova E, et al. Magnetic resonance imaging of active sacroiliitis: do we really need gadolinium? *Eur J Radiol* 2009;71:232-6.
2. Baraliakos X, Hermann KG, Landewé R, et al. Assessment of acute spinal inflammation in patients with ankylosing spondylitis by magnetic resonance imaging: a comparison between contrast enhanced T1 and short tau inversion recovery (STIR) sequences. *Ann Rheum Dis* 2005;64:1141-4.
3. Baraliakos X, Davis J, Tsuji W, et al. Magnetic resonance imaging examinations of the spine in patients with ankylosing spondylitis before and after therapy with the tumor necrosis factor alpha receptor fusion protein etanercept. *Arthritis Rheum* 2005;52:1216-23.
4. Blachier M, Coutanceau B, Dougados M, et al. Does the site of magnetic resonance imaging abnormalities match the site of recent-onset inflammatory back pain? The DESIR cohort. *Ann Rheum Dis* 2013;72:979-85.
5. Bonel HM, Boller C, Saar B, et al. Short-term changes in magnetic resonance imaging and disease activity in response to infliximab. *Ann Rheum Dis* 2010;69:120-5.
6. Braun J, Baraliakos X, Golder W, et al. Magnetic resonance imaging examinations of the spine in patients with ankylosing spondylitis, before and after successful therapy with infliximab: evaluation of a new scoring system. *Arthritis Rheum* 2003;48:1126-36.
7. Braun J, Baraliakos X, Hermann KG, et al. Golimumab reduces spinal inflammation in ankylosing spondylitis: MRI results of the randomised, placebo- controlled GO-RAISE study. *Ann Rheum Dis* 2012;71:878-84.
8. de Hooze M, van den Berg R, Navarro-Compán V, et al. Magnetic resonance imaging of the sacroiliac joints in the early detection of spondyloarthritis: no added value of gadolinium compared with short tau inversion recovery sequence. *Rheumatology (Oxford)* 2013;52:1220-4.
9. Goh L, Suresh P, Gafoor A, et al. Disease activity in longstanding ankylosing spondylitis: a correlation of clinical and magnetic resonance imaging findings. *Clin Rheumatol* 2008;27:449-55.

10. Hermann KG, Landewé RB, Braun J, et al. Magnetic resonance imaging of inflammatory lesions in the spine in ankylosing spondylitis clinical trials: is paramagnetic contrast medium necessary? *J Rheumatol* 2005;32:2056-60.
11. Hu Z, Xu M, Li Q, et al. Adalimumab significantly reduces inflammation and serum DKK-1 level but increases fatty deposition in lumbar spine in active ankylosing spondylitis. *Int J Rheum Dis* 2012;15:358-65.
12. Kiltz U, Baraliakos X, Karakostas P, et al. The degree of spinal inflammation is similar in patients with axial spondyloarthritis who report high or low levels of disease activity: a cohort study. *Ann Rheum Dis* 2012;71:1207-11.
13. Konca S, Keskin D, Ciliz D, et al. Spinal inflammation by magnetic resonance imaging in patients with ankylosing spondylitis: association with disease activity and outcome parameters. *Rheumatol Int* 2012;32:3765-70.
14. Lambert RG, Salonen D, Rahman P, et al. Adalimumab significantly reduces both spinal and sacroiliac joint inflammation in patients with ankylosing spondylitis: a multicenter, randomized, double-blind, placebo-controlled study. *Arthritis Rheum* 2007;56:4005-14.
15. Lukas C, Braun J, van der Heijde D, et al. Scoring inflammatory activity of the spine by magnetic resonance imaging in ankylosing spondylitis: a multireader experiment. *J Rheumatol* 2007;34:862-70.
16. Machado P, Landewé R, Braun J et al. A stratified model for health outcomes in ankylosing spondylitis. *Ann Rheum Dis* 2011;70:1758-64.
17. Machado P, Landewé RB, Braun J, et al. MRI inflammation and its relation with measures of clinical disease activity and different treatment responses in patients with ankylosing spondylitis treated with a tumour necrosis factor inhibitor. *Ann Rheum Dis* 2012;71:2002-5.
18. Madsen KB, Egund N, Jurik AG. Grading of inflammatory disease activity in the sacroiliac joints with magnetic resonance imaging: comparison between short-tau inversion recovery and gadolinium contrast-enhanced sequences. *J Rheumatol* 2010;37:393-400.
19. Maksymowych WP, Dhillon SS, Park R, Salonen D, Inman RD, Lambert RG. Validation of the spondyloarthritis research consortium of Canada magnetic resonance imaging spinal inflammation index: is it necessary to score the entire spine? *Arthritis Rheum* 2007;57:501-7.
20. Maksymowych WP, Salonen D, Inman RD, et al. Low-dose infliximab (3 mg/kg) significantly reduces spinal inflammation on magnetic resonance imaging in patients with ankylosing spondylitis: a randomized placebo-controlled study. *J Rheumatol* 2010;37:1728-34.
21. Marzo-Ortega H, McGonagle D, Jarrett S, et al. Infliximab in combination with methotrexate in active ankylosing spondylitis: a clinical and imaging study. *Ann Rheum Dis* 2005;64:1568-75.

22. Marzo-Ortega H, McGonagle D, O'Connor P, et al. Baseline and 1-year magnetic resonance imaging of the sacroiliac joint and lumbar spine in very early inflammatory back pain. Relationship between symptoms, HLA-B27 and disease extent and persistence. *Ann Rheum Dis* 2009;68:1721-7.
23. Oostveen J, Prevo R, den Boer J, et al. Early detection of sacroiliitis on magnetic resonance imaging and subsequent development of sacroiliitis on plain radiography. A prospective, longitudinal study. *J Rheumatol* 1999;26:1953-8.
24. Pedersen SJ, Sørensen IJ, Hermann KG, et al. Responsiveness of the Ankylosing Spondylitis Disease Activity Score (ASDAS) and clinical and MRI measures of disease activity in a 1-year follow-up study of patients with axial spondyloarthritis treated with tumour necrosis factor alpha inhibitors. *Ann Rheum Dis* 2010;69:1065-71.
25. Puhakka KB, Jurik AG, Schiøttz-Christensen B, et al. Magnetic resonance imaging of sacroiliitis in early seronegative spondylarthropathy. Abnormalities correlated to clinical and laboratory findings. *Rheumatology (Oxford)* 2004;43:234-7.
26. Puhakka KB, Jurik AG, Schiøttz-Christensen B, et al. MRI abnormalities of sacroiliac joints in early spondylarthropathy: a 1-year follow-up study. *Scand J Rheumatol* 2004;33:332-8.
27. Rudwaleit M, Baraliakos X, Listing J, Brandt J, Sieper J, Braun J. Magnetic resonance imaging of the spine and the sacroiliac joints in ankylosing spondylitis and undifferentiated spondyloarthritis during treatment with etanercept. *Ann Rheum Dis* 2005;64:1305-10.
28. Rudwaleit M, Schwarzlose S, Hilgert ES, et al. MRI in predicting a major clinical response to anti-tumour necrosis factor treatment in ankylosing spondylitis. *Ann Rheum Dis* 2008;67:1276-81.
29. Sieper J, Baraliakos X, Listing J, et al. Persistent reduction of spinal inflammation as assessed by magnetic resonance imaging in patients with ankylosing spondylitis after 2 yrs of treatment with the anti-tumour necrosis factor agent infliximab. *Rheumatology (Oxford)* 2005;44:1525-30.
30. Sieper J, van der Heijde D, Dougados M, et al. Efficacy and safety of adalimumab in patients with non-radiographic axial spondyloarthritis: results of a randomised placebo-controlled trial (ABILITY-1). *Ann Rheum Dis* 2013;72:815-22.
31. Song IH, Hermann K, Haibel H, et al. Effects of etanercept versus sulfasalazine in early axial spondyloarthritis on active inflammatory lesions as detected by whole-body MRI (ESTHER): a 48-week randomised controlled trial. *Ann Rheum Dis* 2011;70:590-6.
32. Visvanathan S, Wagner C, Marini JC, et al. Inflammatory biomarkers, disease activity and spinal disease measures in patients with ankylosing spondylitis after treatment with infliximab. *Ann Rheum Dis* 2008;67:511-7.

33. Weber U, Maksymowych WP, Jurik AG. Validation of whole-body against conventional magnetic resonance imaging for scoring acute inflammatory lesions in the sacroiliac joints of patients with spondylarthritis. *Arthritis Rheum* 2009;61:893-9.
34. Weber U, Lambert RG, Rufibach K, et al. Anterior chest wall inflammation by whole-body magnetic resonance imaging in patients with spondyloarthritis: lack of association between clinical and imaging findings in a cross-sectional study. *Arthritis Res Ther* 2012;14:R3.

**Recommendation 4. Monitoring structural changes in axial SpA**

**Conventional radiography of the SI joints and/or spine may be used for long-term monitoring of structural damage, particularly new bone formation, in axial SpA. If performed, it should not be repeated more frequently than every 2nd year. MRI may provide additional information.**

1. Akgul O, Gulkesen A, Akgol G, et al. MR-defined fat infiltration of the lumbar paravertebral muscles differs between non-radiographic axial spondyloarthritis and established ankylosing spondylitis. *Mod Rheumatol* 2013;23:811-6.
2. Averns HL, Oxtoby J, Taylor HG, et al. Radiological outcome in ankylosing spondylitis: use of the Stoke Ankylosing Spondylitis Spine Score (SASSS). *Br J Rheumatol* 1996;35:373-6.
3. Baraliakos X, Davis J, Tsuji W, et al. Magnetic resonance imaging examinations of the spine in patients with ankylosing spondylitis before and after therapy with the tumor necrosis factor alpha receptor fusion protein etanercept. *Arthritis Rheum* 2005;52:1216-23.
4. Baraliakos X, Listing J, Rudwaleit M, et al. Radiographic progression in patients with ankylosing spondylitis after 2 years of treatment with the tumour necrosis factor alpha antibody infliximab. *Ann Rheum Dis* 2005;64:1462-6.
5. Baraliakos X, Listing J, Rudwaleit M, et al. Development of a radiographic scoring tool for ankylosing spondylitis only based on bone formation: addition of the thoracic spine improves sensitivity to change. *Arthritis Rheum* 2009;61:764-71.
6. Braun J, Baraliakos X, Golder W, et al. Analysing chronic spinal changes in ankylosing spondylitis: a systematic comparison of conventional x rays with magnetic resonance imaging using established and new scoring systems. *Ann Rheum Dis* 2004;63:1046-55.
7. Creemers MC, Franssen MJ, van't Hof MA, et al. Assessment of outcome in ankylosing spondylitis: an extended radiographic scoring system. *Ann Rheum Dis* 2005;64:127-9.
8. Lee JY, Kim JI, Park JY, et al. Cervical spine involvement in longstanding ankylosing spondylitis. *Clin Exp Rheumatol* 2005;23:331-8.
9. Lubrano E, Marchesoni A, Olivieri I, et al. The radiological assessment of axial involvement in psoriatic arthritis: a validation study of the BASRI total and the modified SASSS scoring methods. *Clin Exp Rheumatol* 2009;27:977-80.

10. Machado P, Landewé R, Braun J et al. A stratified model for health outcomes in ankylosing spondylitis. *Ann Rheum Dis* 2011;70:1758-64.
11. Machado P, Landewe R, Braun J, et al. In ankylosing spondylitis, a decrease in MRI spinal inflammation predicts improvement in spinal mobility independently of patient reported symptomatic improvement. *Arthritis Rheum* 2012;64 Suppl 10:563.
12. Madsen KB, Jurik AG. Magnetic resonance imaging grading system for active and chronic spondylarthritis changes in the sacroiliac joint. *Arthritis Care Res (Hoboken)* 2010;62:11-8.
13. Madsen KB, Jurik AG. MRI grading method for active and chronic spinal changes in spondyloarthritis. *Clin Radiol* 2010;65:6-14.
14. Puhakka KB, Jurik AG, Egund N, et al. Imaging of sacroiliitis in early seronegative spondylarthropathy. Assessment of abnormalities by MR in comparison with radiography and CT. *Acta Radiol* 2003;44:218-29.
15. Puhakka KB, Jurik AG, Schiøttz-Christensen B, et al. MRI abnormalities of sacroiliac joints in early spondylarthropathy: a 1-year follow-up study. *Scand J Rheumatol* 2004;33:332-8.
16. Puhakka KB, Jurik AG, Schiøttz-Christensen B, et al. Magnetic resonance imaging of sacroiliitis in early seronegative spondylarthropathy. Abnormalities correlated to clinical and laboratory findings. *Rheumatology (Oxford)* 2004;43:234-7.
17. Ramiro S, van Tubergen A, Stolwijk C, et al. Scoring radiographic progression in ankylosing spondylitis: should we use the modified Stoke Ankylosing Spondylitis Spine Score (mSASSS) or the Radiographic Ankylosing Spondylitis Spinal Score (RASSS)? *Arthritis Res Ther* 2013;15:R14.
18. Rudwaleit M, Baraliakos X, Listing J, et al. Magnetic resonance imaging of the spine and the sacroiliac joints in ankylosing spondylitis and undifferentiated spondyloarthritis during treatment with etanercept. *Ann Rheum Dis* 2005;64:1305-10.
19. Salaffi F, Carotti M, Garofalo G, et al. Radiological scoring methods for ankylosing spondylitis: a comparison between the Bath Ankylosing Spondylitis Radiology Index and the modified Stoke Ankylosing Spondylitis Spine Score. *Clin Exp Rheumatol* 2007;25:67-74.
20. Taylor HG, Wardle T, Beswick EJ, et al. The relationship of clinical and laboratory measurements to radiological change in ankylosing spondylitis. *Br J Rheumatol* 1991;30:330-5.
21. Taylor HG, Gadd R, Beswick EJ, et al. Quantitative radio-isotope scanning in ankylosing spondylitis: a clinical, laboratory and computerised tomographic study. *Scand J Rheumatol* 1991;20:274-9.
22. Wanders AJ, Landewé RB, Spoorenberg A, et al. What is the most appropriate radiologic scoring method for ankylosing spondylitis? A comparison of the available methods based



on the Outcome Measures in Rheumatology Clinical Trials filter. *Arthritis Rheum* 2004;50:2622-32.

23. Williamson L, Dockerty JL, Dalbeth N, et al. Clinical assessment of sacroiliitis and HLA-B27 are poor predictors of sacroiliitis diagnosed by magnetic resonance imaging in psoriatic arthritis. *Rheumatology (Oxford)* 2004;43:85-8.

#### **Recommendation 5. Monitoring disease activity in peripheral SpA**

**US and MRI may be used to monitor disease activity (particularly synovitis and enthesitis) in peripheral SpA, providing additional information on top of clinical and biochemical assessments. The decision on when to repeat US/MRI depends on the clinical circumstances. US with high-sensitivity colour or power Doppler is sufficient to detect inflammation and the use of US contrast medium is not needed.**

1. Aydin SZ, Ash ZR, Tinazzi I, et al. The link between enthesitis and arthritis in psoriatic arthritis: a switch to a vascular phenotype at insertions may play a role in arthritis development. *Ann Rheum Dis* 2013;72:992-5.
2. Aydin SZ, Karadag O, Filippucci E, et al. Monitoring Achilles enthesitis in ankylosing spondylitis during TNF-alpha antagonist therapy: an ultrasound study. *Rheumatology (Oxford)* 2010;49:578-82.
3. Balint PV, Kane D, Wilson H, et al. Ultrasonography of enthesal insertions in the lower limb in spondyloarthritis. *Ann Rheum Dis* 2002;61:905-10.
4. Bennett AN, Marzo-Ortega H, Tan AL, et al. Ten-year follow-up of SpA-related oligoarthritis involving the knee: the presence of psoriasis but not HLA-B27 or baseline MRI bone oedema predicts outcome. *Rheumatology (Oxford)* 2012;51:1099-106.
5. Borman P, Koparal S, Babaoğlu S, et al. Ultrasound detection of enthesal insertions in the foot of patients with spondyloarthritis. *Clin Rheumatol* 2006;25:373-7.
6. D'Agostino MA, Said-Nahal R, Hacquard-Bouder C, et al. Assessment of peripheral enthesitis in the spondylarthropathies by ultrasonography combined with power Doppler: a cross-sectional study. *Arthritis Rheum* 2003;48:523-33.
7. Hamdi W, Chelli-Bouaziz M, Ahmed MS, et al. Correlations among clinical, radiographic, and sonographic scores for enthesitis in ankylosing spondylitis. *Joint Bone Spine* 2011;78:270-4.
8. Kiris A, Kaya A, Ozgocmen S, Kocakoc E. Assessment of enthesitis in ankylosing spondylitis by power Doppler ultrasonography. *Skeletal Radiol* 2006;35:522-8.
9. McQueen F, Lassere M, Duer-Jensen A, et al. Testing an OMERACT MRI scoring system for peripheral psoriatic arthritis in cross-sectional and longitudinal settings. *J Rheumatol* 2009;36:1811-5.
10. Mease P, Genovese MC, Gladstein G, et al. Abatacept in the treatment of patients with psoriatic arthritis: results of a six-month, multicenter, randomized, double-blind, placebo-controlled, phase II trial. *Arthritis Rheum* 2011;63:939-48.

11. Milosavljevic J, Lindqvist U, Elvin A. Ultrasound and power Doppler evaluation of the hand and wrist in patients with psoriatic arthritis. *Acta Radiol* 2005;46:374-85.
12. Naredo E, Batlle-Gualda E, García-Vivar ML, et al. Power Doppler ultrasonography assessment of entheses in spondyloarthropathies: response to therapy of enthesal abnormalities. *J Rheumatol* 2010;37:2110-7.
13. Poggenborg RP, Boyesen P, Wiell C, et al. Reduction in MRI inflammation during adalimumab therapy in patients with psoriatic arthritis implementation of the OMERACT PsAMRIS scoring method in a follow-up study. *Arthritis Rheum* 2011;63 Suppl 10:953.
14. Spadaro A, Iagnocco A, Perrotta FM, et al. Clinical and ultrasonography assessment of peripheral enthesitis in ankylosing spondylitis. *Rheumatology (Oxford)* 2011;50:2080-6.
15. Tan YM, Østergaard M, Doyle A, et al. MRI bone oedema scores are higher in the arthritis mutilans form of psoriatic arthritis and correlate with high radiographic scores for joint damage. *Arthritis Res Ther* 2009;11:R2.

**Recommendation 6. Monitoring structural changes in peripheral SpA**  
**In peripheral SpA, if the clinical scenario requires monitoring of structural damage, then conventional radiography is recommended. MRI and/or US might provide additional information.**

1. Blackmore MG, Gladman DD, Husted J, et al. Measuring health status in psoriatic arthritis: the Health Assessment Questionnaire and its modification. *J Rheumatol* 1995;22:886-93.
2. Borman P, Koparal S, Babaoğlu S, et al. Ultrasound detection of enthesal insertions in the foot of patients with spondyloarthropathy. *Clin Rheumatol* 2006;25:373-7.
3. Hamdi W, Chelli-Bouaziz M, Ahmed MS, et al. Correlations among clinical, radiographic, and sonographic scores for enthesitis in ankylosing spondylitis. *Joint Bone Spine* 2011;78:270-4.
4. Könönen M, Kovero O, Wenneberg B, et al. Radiographic signs in the temporomandibular joint in Reiter's disease. *J Orofac Pain* 2002;16:143-7.
5. Rahman P, Gladman DD, Cook RJ, et al. Radiological assessment in psoriatic arthritis. *Br J Rheumatol* 1998;37:760-5.
6. Ravindran J, Cavill C, Balakrishnan C, et al. A modified Sharp score demonstrates disease progression in established psoriatic arthritis. *Arthritis Care Res (Hoboken)* 2010;62:86-91.
7. Taccari E, Spadaro A, Rinaldi T, et al. Comparison of the Health Assessment Questionnaire and Arthritis Impact Measurement Scale in patients with psoriatic arthritis. *Rev Rhum Engl Ed* 1998;65:751-8.

8. Tan YM, Østergaard M, Doyle A, et al. MRI bone oedema scores are higher in the arthritis mutilans form of psoriatic arthritis and correlate with high radiographic scores for joint damage. *Arthritis Res Ther* 2009;11:R2.

#### **Recommendation 7. Predicting outcome/severity in axial SpA**

**In patients with ankylosing spondylitis\* (not non-radiographic axial SpA), initial conventional radiography of the lumbar and cervical spine is recommended to detect syndesmophytes, which are predictive of development of new syndesmophytes. MRI (vertebral corner inflammatory or fatty lesions) may also be used to predict development of new radiographic syndesmophytes.**

**\*i.e. radiographic axial spondyloarthritis**

1. Aaverns HL, Oxtoby J, Taylor HG, et al. Radiological outcome in ankylosing spondylitis: use of the Stoke Ankylosing Spondylitis Spine Score (SASSS). *Br J Rheumatol* 1996;35:373-6.
2. Baraliakos X, Listing J, Rudwaleit M, et al. Radiographic progression in patients with ankylosing spondylitis after 2 years of treatment with the tumour necrosis factor alpha antibody infliximab. *Ann Rheum Dis* 2005;64:1462-6.
3. Baraliakos X, Listing J, Rudwaleit M, et al. Progression of radiographic damage in patients with ankylosing spondylitis: defining the central role of syndesmophytes. *Ann Rheum Dis* 2007;66:910-5.
4. Baraliakos X, Listing J, Rudwaleit M, et al. The relationship between inflammation and new bone formation in patients with ankylosing spondylitis. *Arthritis Res Ther* 2008;10:R104.
5. Baraliakos X, Listing J, von der Recke A, et al. The natural course of radiographic progression in ankylosing spondylitis-evidence for major individual variations in a large proportion of patients. *J Rheumatol* 2009;36:997-1002.
6. Baraliakos X, Heldmann F, Listing J, et al. The relationship of inflammation, fatty degeneration and the effect of long-term TNF-blocker treatment on the development of new bone formation in patients with ankylosing spondylitis. *Arthritis Rheum* 2012;64 Suppl 10:780.
7. Bennett AN, McGonagle D, O'Connor P, et al. Severity of baseline magnetic resonance imaging-evident sacroiliitis and HLA-B27 status in early inflammatory back pain predict radiographically evident ankylosing spondylitis at eight years. *Arthritis Rheum* 2008;58:3413-8.
8. Chiowchanwisawakit P, Lambert RG, Conner-Spady B, et al. Focal fat lesions at vertebral corners on magnetic resonance imaging predict the development of new syndesmophytes in ankylosing spondylitis. *Arthritis Rheum* 2011;63:2215-25.
9. Madsen KB, Schiøttz-Christensen B, Jurik AG. Prognostic significance of magnetic resonance imaging changes of the sacroiliac joints in spondyloarthritis-a followup study. *J Rheumatol* 2010;37:1718-27.

10. Maksymowych WP, Landewé R, Conner-Spady B, et al. Serum matrix metalloproteinase 3 is an independent predictor of structural damage progression in patients with ankylosing spondylitis. *Arthritis Rheum* 2007;56:1846-53.
11. Maksymowych WP, Chiowchanwisawakit P, Clare T, et al. Inflammatory lesions of the spine on magnetic resonance imaging predict the development of new syndesmophytes in ankylosing spondylitis: evidence of a relationship between inflammation and new bone formation. *Arthritis Rheum* 2009;60:93-102.
12. Pedersen SJ, Chiowchanwisawakit P, Lambert RG, et al. Resolution of inflammation following treatment of ankylosing spondylitis is associated with new bone formation. *J Rheumatol* 2011;38:1349-54.
13. Pedersen SJ, Sørensen IJ, Lambert RG, et al. Radiographic progression is associated with resolution of systemic inflammation in patients with axial spondylarthritis treated with tumor necrosis factor  $\alpha$  inhibitors: a study of radiographic progression, inflammation on magnetic resonance imaging, and circulating biomarkers of inflammation, angiogenesis, and cartilage and bone turnover. *Arthritis Rheum* 2011;63:3789-800.
14. Poddubnyy D, Haibel H, Listing J, et al. Baseline radiographic damage, elevated acute-phase reactant levels, and cigarette smoking status predict spinal radiographic progression in early axial spondylarthritis. *Arthritis Rheum* 2012;64:1388-98.
15. Song IH, Hermann KG, Haibel H, Althoff CE, Poddubnyy D, Listing J, Weiss A, Freundlich B, Rudwaleit M, Sieper J. Relationship between active inflammatory lesions in the spine and sacroiliac joints and new development of chronic lesions on whole-body MRI in early axial spondyloarthritis: results of the ESTHER trial at week 48. *Ann Rheum Dis* 2011;70:1257-63.
16. van der Heijde D, Machado P, Braun J, et al. MRI inflammation at the vertebral unit only marginally predicts new syndesmophyte formation: a multilevel analysis in patients with ankylosing spondylitis. *Ann Rheum Dis* 2012;71:369-73.
17. van Tubergen A, Ramiro S, van der Heijde D, et al. Development of new syndesmophytes and bridges in ankylosing spondylitis and their predictors: a longitudinal study. *Ann Rheum Dis* 2012;71:518-23.

**Recommendation 8. Predicting treatment effect in axial SpA**

**Extensive MRI inflammatory activity (bone marrow edema), particularly in the spine in ankylosing spondylitis patients, might be used as a predictor of good clinical response to anti-TNF treatment in axial SpA. Thus, MRI might aid in the decision of initiating anti-TNF therapy, in addition to clinical examination and CRP.**

1. Barkham N, Keen HI, Coates LC, et al. Clinical and imaging efficacy of infliximab in HLA-B27-Positive patients with magnetic resonance imaging-determined early sacroiliitis. *Arthritis Rheum* 2009;60:946-54.
2. Rudwaleit M, Schwarzlose S, Hilgert ES, et al. MRI in predicting a major clinical response to anti-tumour necrosis factor treatment in ankylosing spondylitis. *Ann Rheum Dis* 2008;67:1276-81.

3. Sieper J, Baraliakos X, Listing J, et al. Persistent reduction of spinal inflammation as assessed by magnetic resonance imaging in patients with ankylosing spondylitis after 2 yrs of treatment with the anti-tumour necrosis factor agent infliximab. *Rheumatology (Oxford)* 2005;44:1525-30.

#### **Recommendation 9. Spinal fracture**

**When spinal fracture in axial SpA is suspected, conventional radiography is the recommended initial imaging method. If conventional radiography is negative, CT should be performed. MRI is an additional imaging method to CT, which can also provide information on soft tissue lesions.**

-

#### **Recommendation 10. Osteoporosis**

**In axial SpA patients without syndesmophytes in the lumbar spine on conventional radiography, osteoporosis should be assessed by hip DXA and AP-spine DXA. In patients with syndesmophytes in the lumbar spine on conventional radiography, osteoporosis should be assessed by hip DXA, supplemented by either spine DXA in lateral projection or possibly QCT of the spine.**

1. Altindag O, Karakoc M, Soran N, Tabur H, Demirkol A. Bone mineral density in patients with ankylosing spondylitis. *Romatizma* 2008;23:42-5.
2. Anandarajah AP, El-Taha M, Peng C, Reed G, Greenberg JD, Ritchlin CT. Association between focal erosions and generalised bone loss in psoriatic arthritis. *Ann Rheum Dis* 2011;70:1345-7.
3. Arends S, Spoorenberg A, Bruyn GA, Houtman PM, Leijnsma MK, Kallenberg CG, Brouwer E, van der Veer E. The relation between bone mineral density, bone turnover markers, and vitamin D status in ankylosing spondylitis patients with active disease: a cross-sectional analysis. *Osteoporos Int* 2011;22:1431-9.
4. Baek HJ, Kang SW, Lee YJ, Shin KC, Lee EB, Yoo CD, Song YW. Osteopenia in men with mild and severe ankylosing spondylitis. *Rheumatol Int* 2005;26:30-4.
5. Briot K, Durnez A, Paternotte S, Miceli-Richard C, Dougados M, Roux C. Bone oedema on MRI is highly associated with low bone mineral density in patients with early inflammatory back pain: results from the DESIR cohort. *Ann Rheum Dis* 2013;72:1914-9.
6. Capaci K, Hepguler S, Argin M, Tas I. Bone mineral density in mild and advanced ankylosing spondylitis. *Yonsei Med J* 2003;44:379-84.
7. Devogelaer JP, Maldague B, Malghem J, Nagant de Deuxchaisnes C. Appendicular and vertebral bone mass in ankylosing spondylitis. A comparison of plain radiographs with single- and dual-photon absorptiometry and with quantitative computed tomography. *Arthritis Rheum* 2002;35:1062-7.
8. Dheda K, Cassim B, Patel N, Mody GM. A comparison of bone mineral density in Indians with psoriatic polyarthritis and healthy Indian volunteers. *Clin Rheumatol* 2004;23:89.

9. Donnelly S, Doyle DV, Denton A, Rolfe I, McCloskey EV, Spector TD. Bone mineral density and vertebral compression fracture rates in ankylosing spondylitis. *Ann Rheum Dis* 1994;53:117-21.
10. Dos Santos FP, Constantin A, Laroche M, Destombes F, Bernard J, Mazières B, Cantagrel A. Whole body and regional bone mineral density in ankylosing spondylitis. *J Rheumatol* 2001;28:547-9.
11. El Maghraoui A, Borderie D, Cherruau B, Edouard R, Dougados M, Roux C. Osteoporosis, body composition, and bone turnover in ankylosing spondylitis. *J Rheumatol* 1999;26:2205-9.
12. Frediani B, Allegri A, Falsetti P, Storri L, Bisogno S, Baldi F, Filipponi P, Marcolongo R. Bone mineral density in patients with psoriatic arthritis. *J Rheumatol* 2001;28:138-43.
13. Franck H, Meurer T, Hofbauer LC. Evaluation of bone mineral density, hormones, biochemical markers of bone metabolism, and osteoprotegerin serum levels in patients with ankylosing spondylitis. *J Rheumatol* 2004;31:2236-41.
14. Gilgil E, Kaçar C, Tuncer T, Bütün B. The association of syndesmophytes with vertebral bone mineral density in patients with ankylosing spondylitis. *J Rheumatol* 2005;32:292-4.
15. Gratacós J, Collado A, Pons F, Osaba M, Sanmartí R, Roqué M, Larrosa M, Muñoz-Gómez J. Significant loss of bone mass in patients with early, active ankylosing spondylitis: a followup study. *Arthritis Rheum* 1999;42:2319-24.
16. Grazio S, Cvijetić S, Vlak T, Grubišić F, Matijević V, Nemčić T, Punda M, Kusić Z. Osteoporosis in psoriatic arthritis: is there any? *Wien Klin Wochenschr* 2011;123:743-50.
17. Grazio S, Kusić Z, Cvijetić S, Grubišić F, Balenović A, Nemčić T, Matijević-Mikelić V, Punda M, Sieper J. Relationship of bone mineral density with disease activity and functional ability in patients with ankylosing spondylitis: a cross-sectional study. *Rheumatol Int* 2012;32:2801-8.
18. Grisar J, Bernecker PM, Aringer M, Redlich K, Sedlak M, Wolozczuk W, Spitzauer S, Grampp S, Kainberger F, Ebner W, Smolen JS, Pietschmann P. Ankylosing spondylitis, psoriatic arthritis, and reactive arthritis show increased bone resorption, but differ with regard to bone formation. *J Rheumatol* 2002;29:1430-6.
19. Haugeberg G, Bennett AN, McGonagle D, Emery P, Marzo-Ortega H. Bone loss in very early inflammatory back pain in undifferentiated spondyloarthropathy: a 1-year observational study. *Ann Rheum Dis* 2010;69:1364-6.
20. Jansen TL, Aarts MH, Zanen S, Bruyn GA. Risk assessment for osteoporosis by quantitative ultrasound of the heel in ankylosing spondylitis. *Clin Exp Rheumatol* 2003;21:599-604.
21. Jun JB, Joo KB, Her MY, Kim TH, Bae SC, Yoo DH, Kim SK. Femoral bone mineral density is associated with vertebral fractures in patients with ankylosing spondylitis: a cross-sectional study. *J Rheumatol* 2006;33:1637-41.

22. Karberg K, Zochling J, Sieper J, Felsenberg D, Braun J. Bone loss is detected more frequently in patients with ankylosing spondylitis with syndesmophytes. *J Rheumatol* 2005;32:1290-8.
23. Kaya A, Ozgocmen S, Kamanli A, Ardicoglu O. Bone loss in ankylosing spondylitis: does syndesmophyte formation have an influence on bone density changes? *Med Princ Pract* 2009;18:470-6.
24. Klingberg E, Lorentzon M, Mellström D, Geijer M, Göthlin J, Hilme E, Hedberg M, Carlsten H, Forsblad-d'Elia H. Osteoporosis in ankylosing spondylitis - prevalence, risk factors and methods of assessment. *Arthritis Res Ther* 2012;14:R108.
25. Korczowska I, Przepiera-Bedzak H, Brzosko M, Lacki JK, Trefler J, Hrycaj P. Bone tissue metabolism in men with ankylosing spondylitis. *Adv Med Sci* 2011;56:264-9.
26. Maillefert JF, Aho LS, El Maghraoui A, Dougados M, Roux C. Changes in bone density in patients with ankylosing spondylitis: a two-year follow-up study. *Osteoporos Int* 2001;12:605-9.
27. Meirelles ES, Borelli A, Camargo OP. Influence of disease activity and chronicity on ankylosing spondylitis bone mass loss. *Clin Rheumatol* 1999;18:364-8.
28. Mermerci Başkan B, Pekin Doğan Y, Sivas F, Bodur H, Ozoran K. The relation between osteoporosis and vitamin D levels and disease activity in ankylosing spondylitis. *Rheumatol Int* 2010;30:375-81.
29. Mitra D, Elvins DM, Collins AJ. Biochemical markers of bone metabolism in mild ankylosing spondylitis and their relationship with bone mineral density and vertebral fractures. *J Rheumatol* 1999;26:2201-4.
30. Mullaji AB, Upadhyay SS, Ho EK. Bone mineral density in ankylosing spondylitis. DEXA comparison of control subjects with mild and advanced cases. *J Bone Joint Surg Br* 1994;76:660-5.
31. Muntean L, Rojas-Vargas M, Font P, Simon SP, Rednic S, Schiotis R, Stefan S, Tamas MM, Bolosiu HD, Collantes-Estévez E. Relative value of the lumbar spine and hip bone mineral density and bone turnover markers in men with ankylosing spondylitis. *Clin Rheumatol* 2011;30:691-5.
32. Park MC, Chung SJ, Park YB, Lee SK. Bone and cartilage turnover markers, bone mineral density, and radiographic damage in men with ankylosing spondylitis. *Yonsei Med J* 2008;49:288-94.
33. Pedreira PG, Pinheiro MM, Szejnfeld VL. Bone mineral density and body composition in postmenopausal women with psoriasis and psoriatic arthritis. *Arthritis Res Ther* 2011;13:R16.
34. Sarikaya S, Basaran A, Tekin Y, Ozdolap S, Ortancil O. Is osteoporosis generalized or localized to central skeleton in ankylosing spondylitis? *J Clin Rheumatol* 2007;13:20-4.

35. Speden DJ, Calin AI, Ring FJ, Bhalla AK. Bone mineral density, calcaneal ultrasound, and bone turnover markers in women with ankylosing spondylitis. *J Rheumatol* 2002;29:516-21.
36. Taylan A, Sari I, Akinci B, Bilge S, Kozaci D, Akar S, Colak A, Yalcin H, Gunay N, Akkoc N. Biomarkers and cytokines of bone turnover: extensive evaluation in a cohort of patients with ankylosing spondylitis. *BMC Musculoskelet Disord* 2012;13:191.
37. Toussiroot E, Michel F, Wendling D. Bone density, ultrasound measurements and body composition in early ankylosing spondylitis. *Rheumatology (Oxford)* 2001;40:882-8.
38. Ulu MA, Çevik R, Dilek B. Comparison of PA spine, lateral spine, and femoral BMD measurements to determine bone loss in ankylosing spondylitis. *Rheumatol Int* 2012;29:29.
39. van der Weijden MA, van Denderen JC, Lems WF, Heymans MW, Dijkmans BA, van der Horst-Bruinsma IE. Low bone mineral density is related to male gender and decreased functional capacity in early spondylarthropathies. *Clin Rheumatol* 2011;30:497-503.
40. Vasdev V, Bhakuni D, Garg MK, Narayanan K, Jain R, Chadha D. "Bone mineral density in young males with ankylosing spondylitis. *Int J Rheum Dis* 2011;14:68-73.
41. Will R, Palmer R, Bhalla AK, Ring F, Calin A. Osteoporosis in early ankylosing spondylitis: a primary pathological event? *Lancet* 1989;2:1483-5.
42. Will R, Palmer R, Bhalla AK, Ring F, Calin A. Bone loss as well as bone formation is a feature of progressive ankylosing spondylitis. *Br J Rheumatol* 1990;29:498-9.

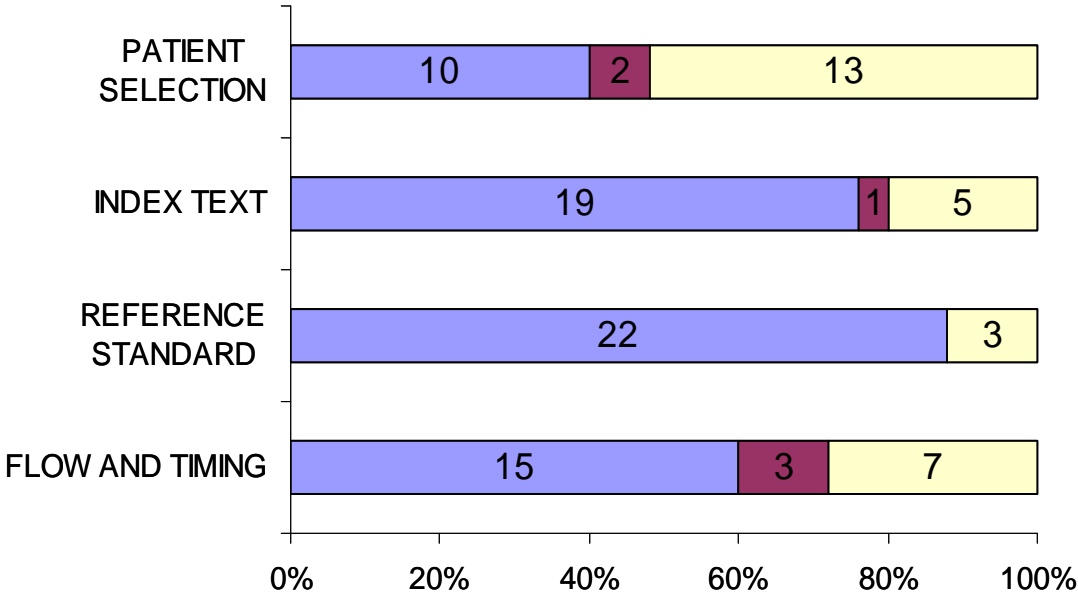


**S6. Quality assessment of included studies for individual recommendations (R) with QUADAS-2**

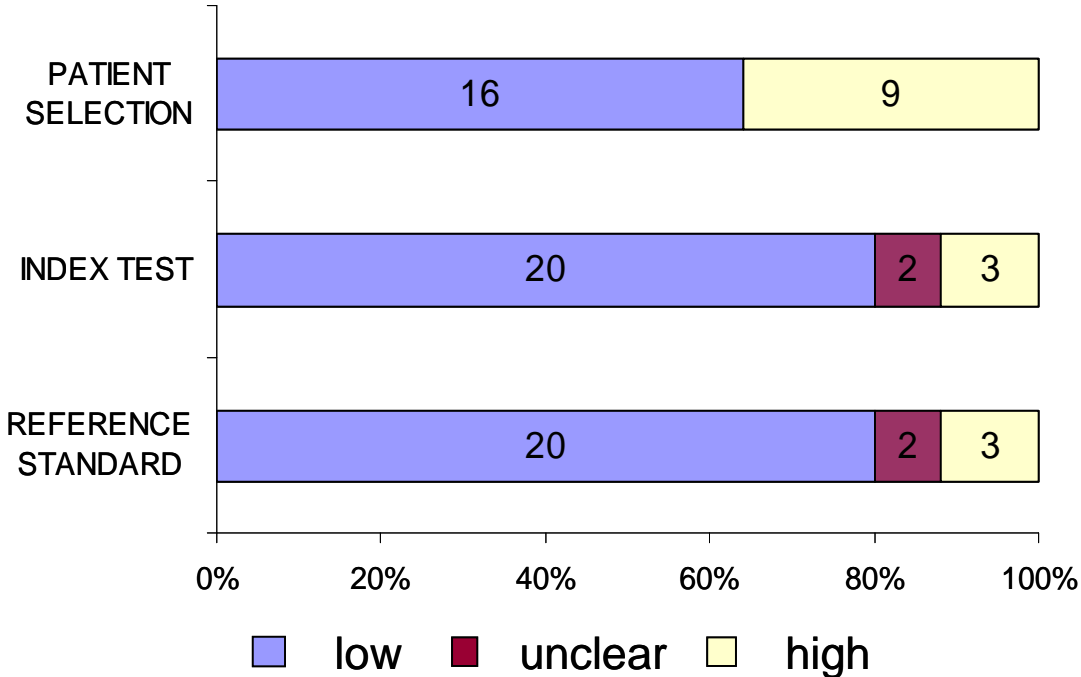
**S6.1**

**R1**

**Risk of bias**

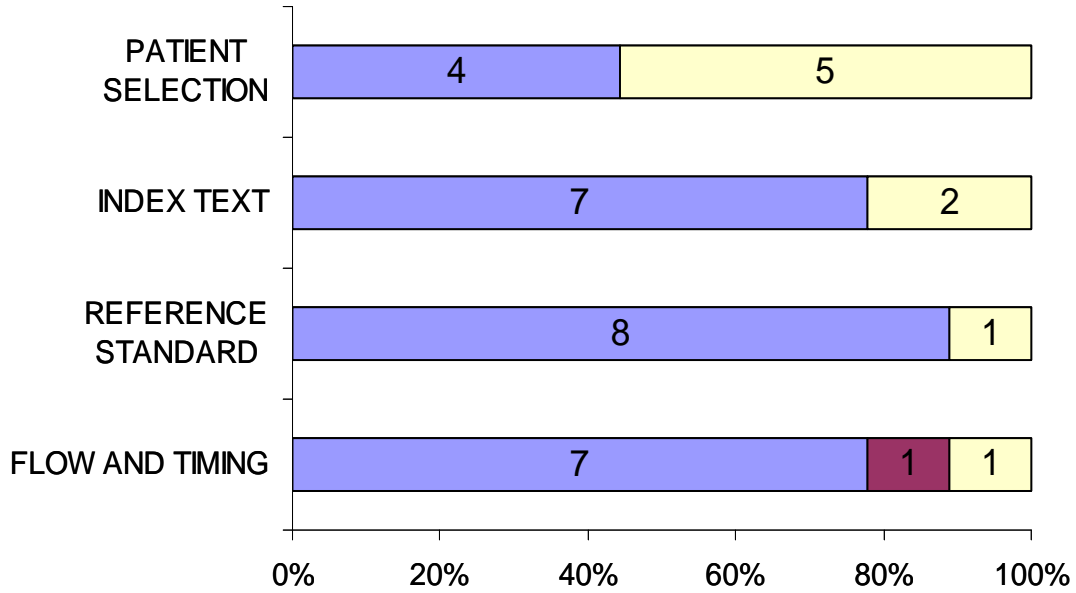


**Applicability concerns**

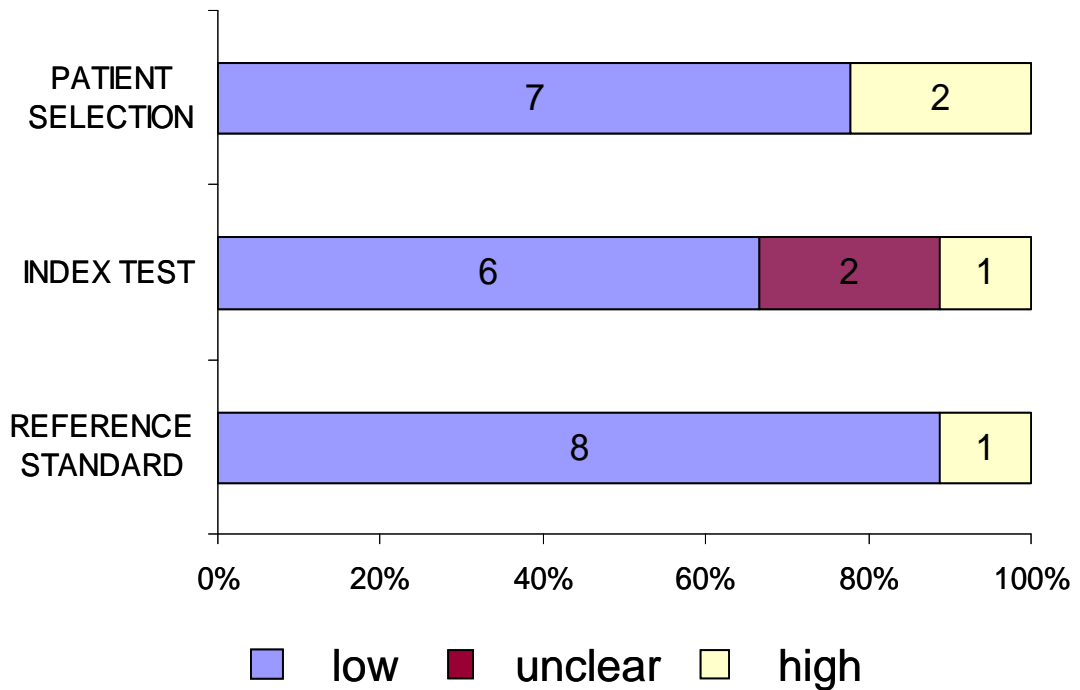


R2

Risk of bias

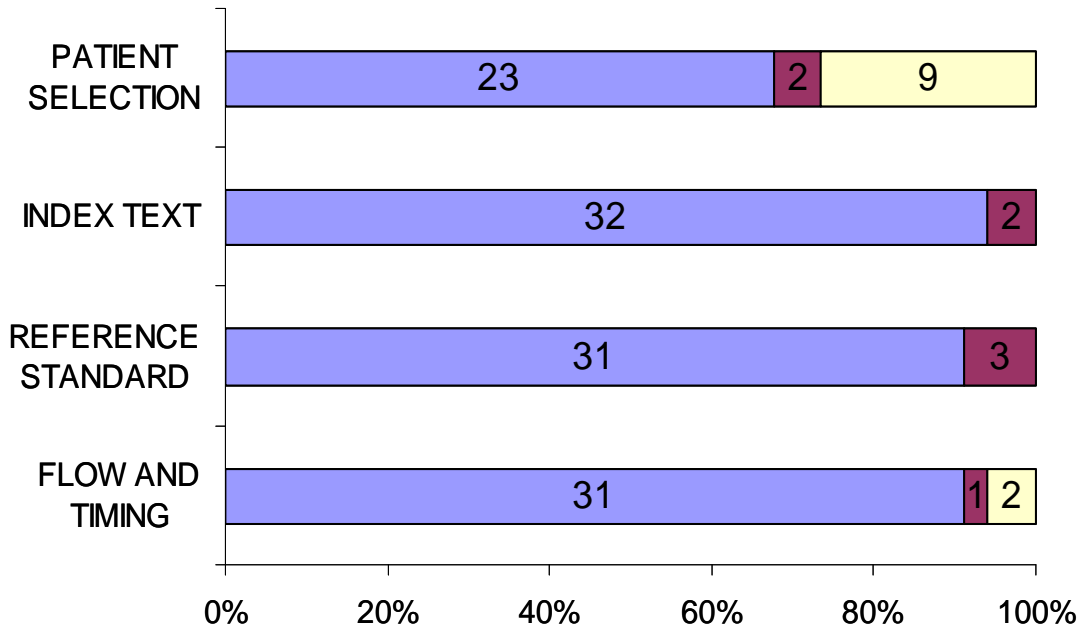


Applicability concerns

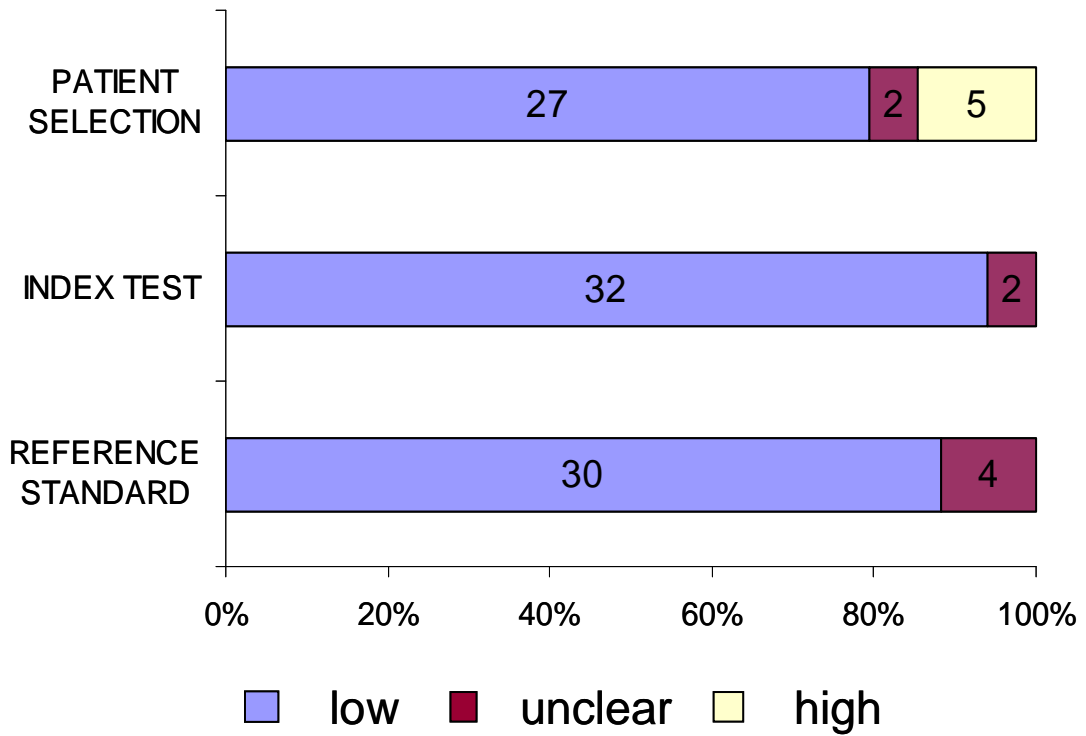


R3

Risk of bias

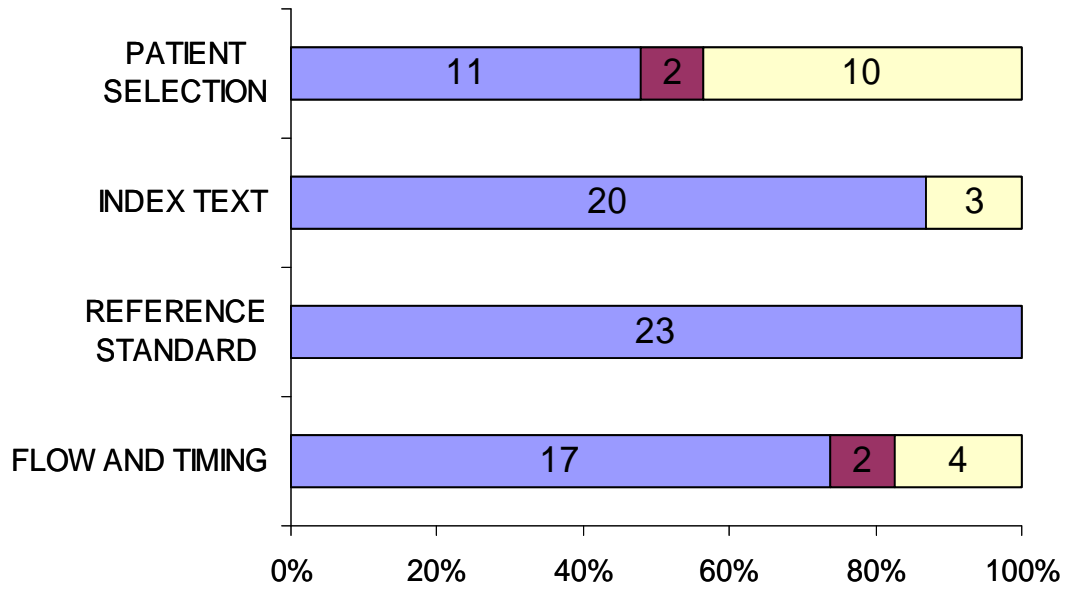


Applicability concerns

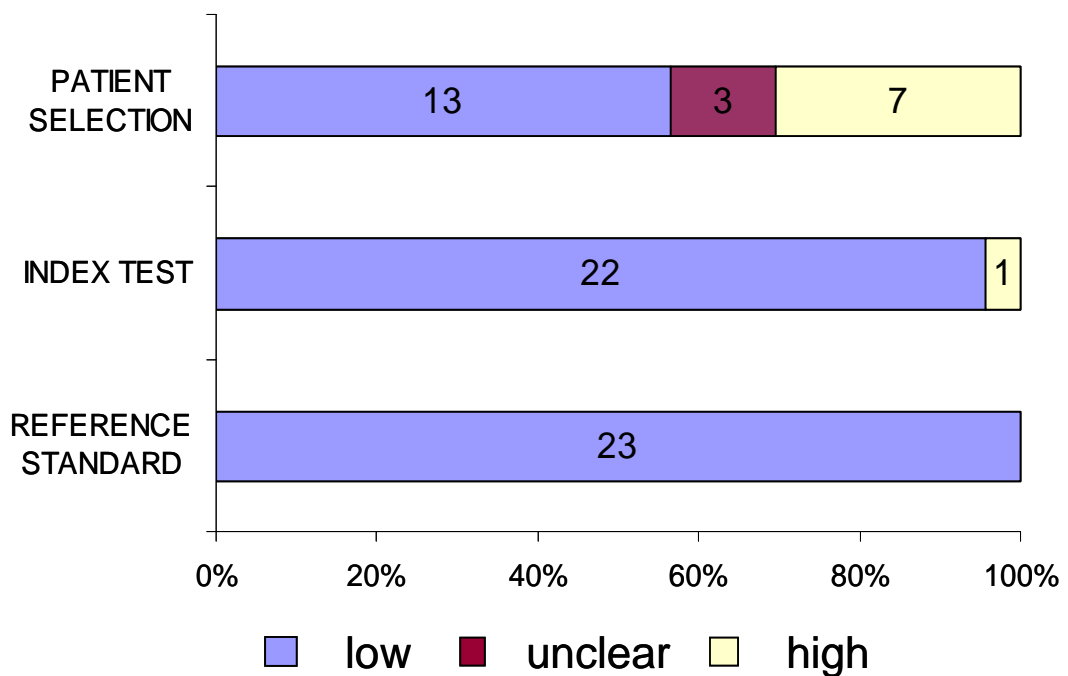


R4

Risk of bias

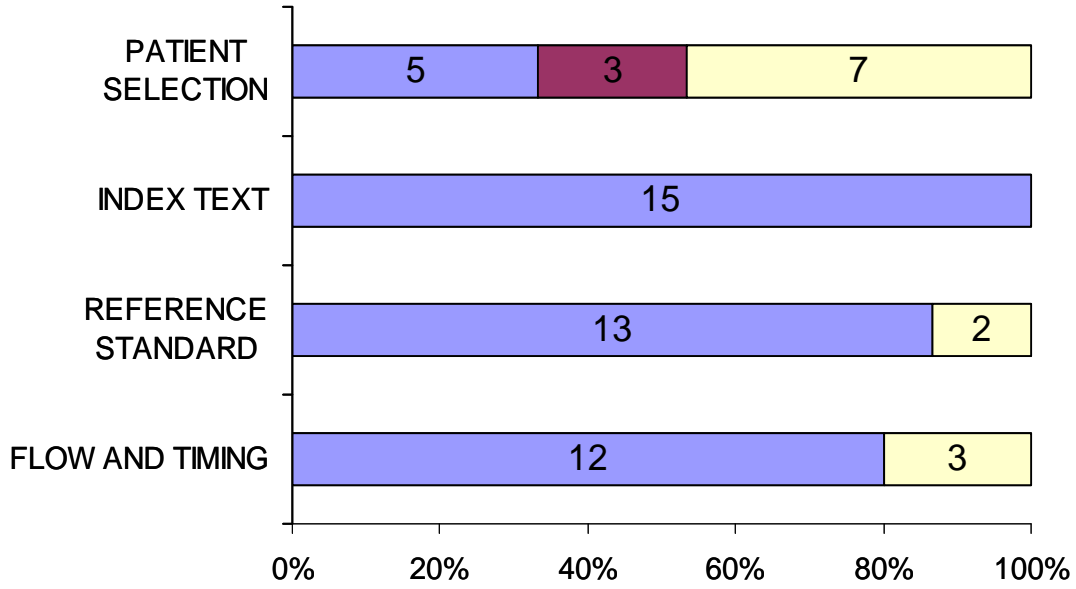


Applicability concerns

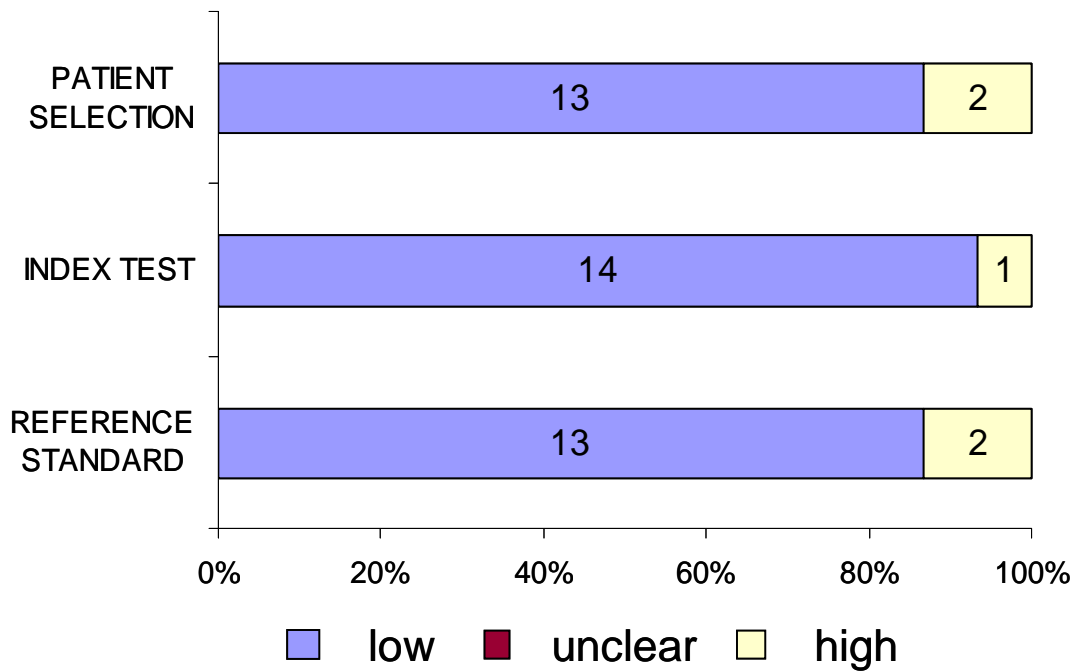


R5

Risk of bias

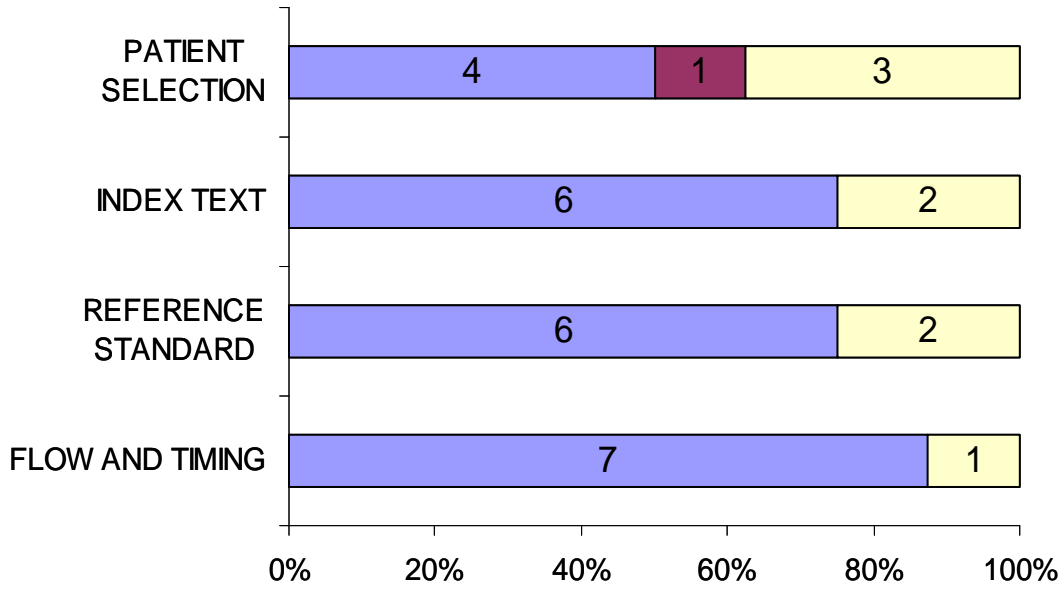


Applicability concerns

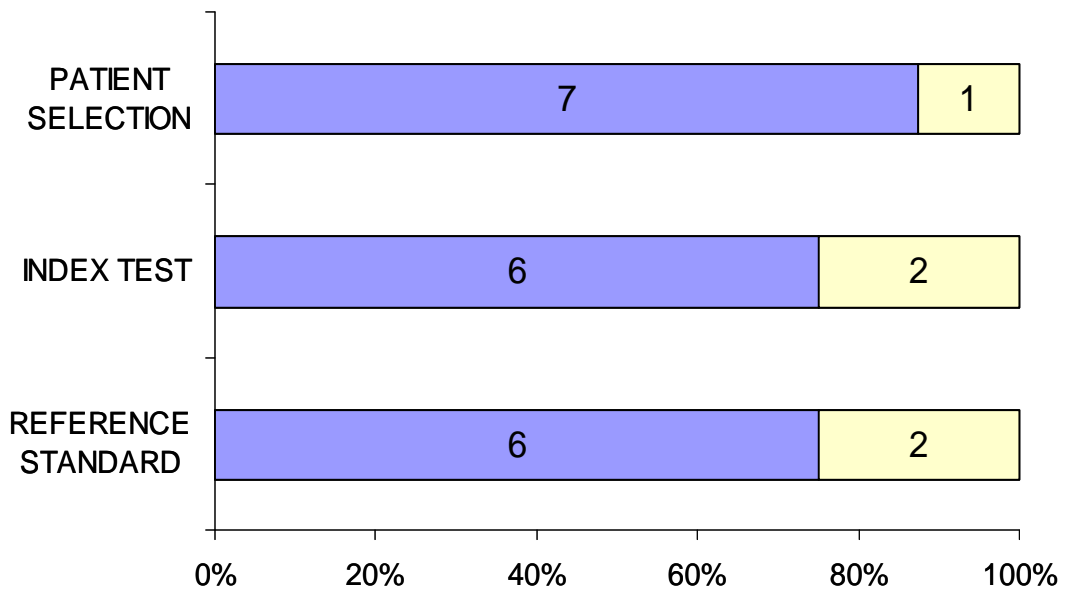


R6

Risk of bias



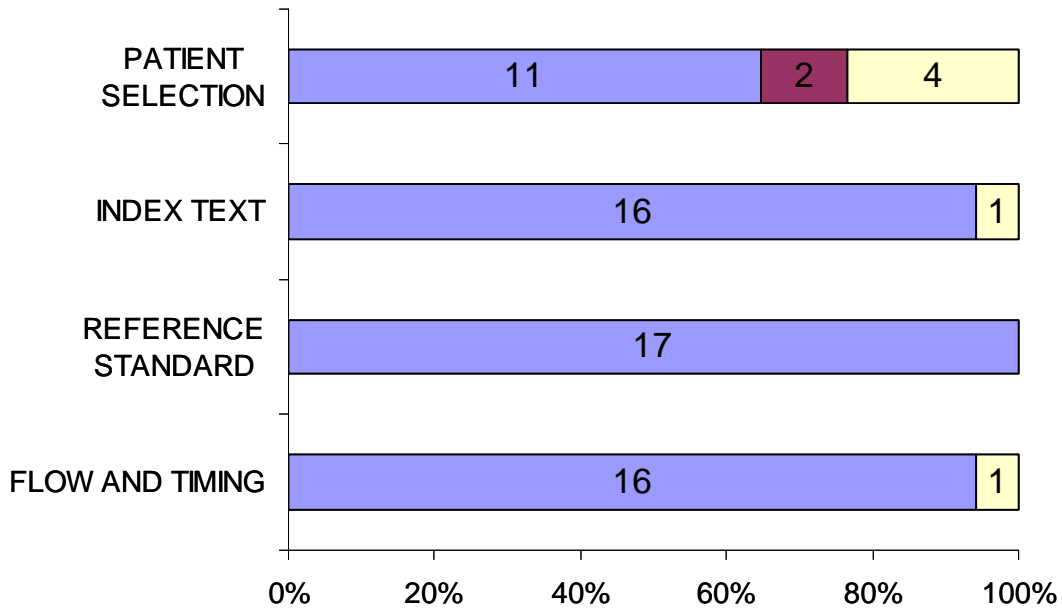
Applicability concerns



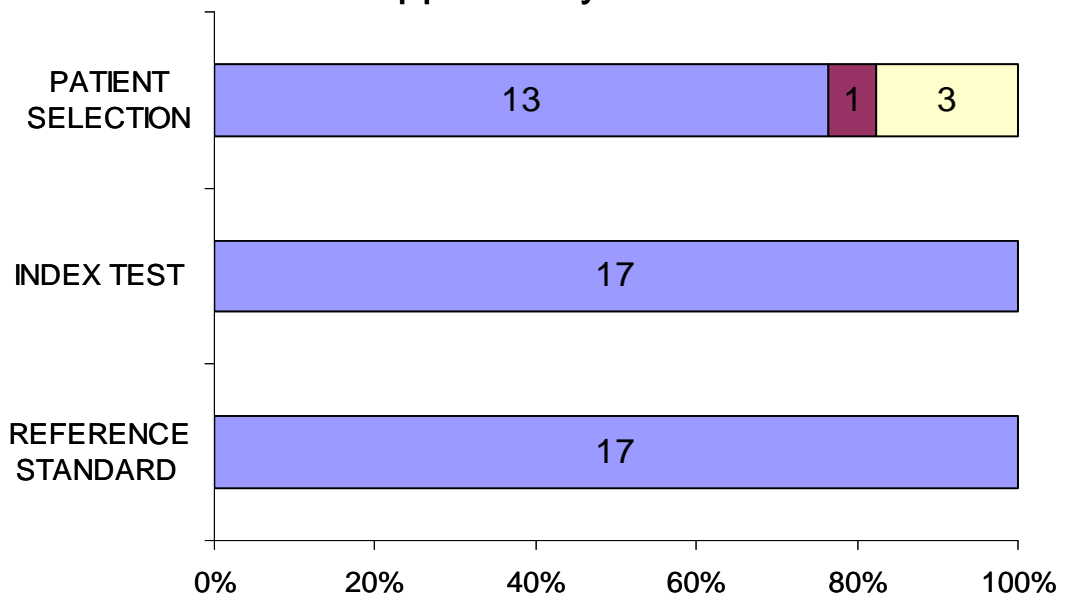
low unclear high

R7

Risk of bias



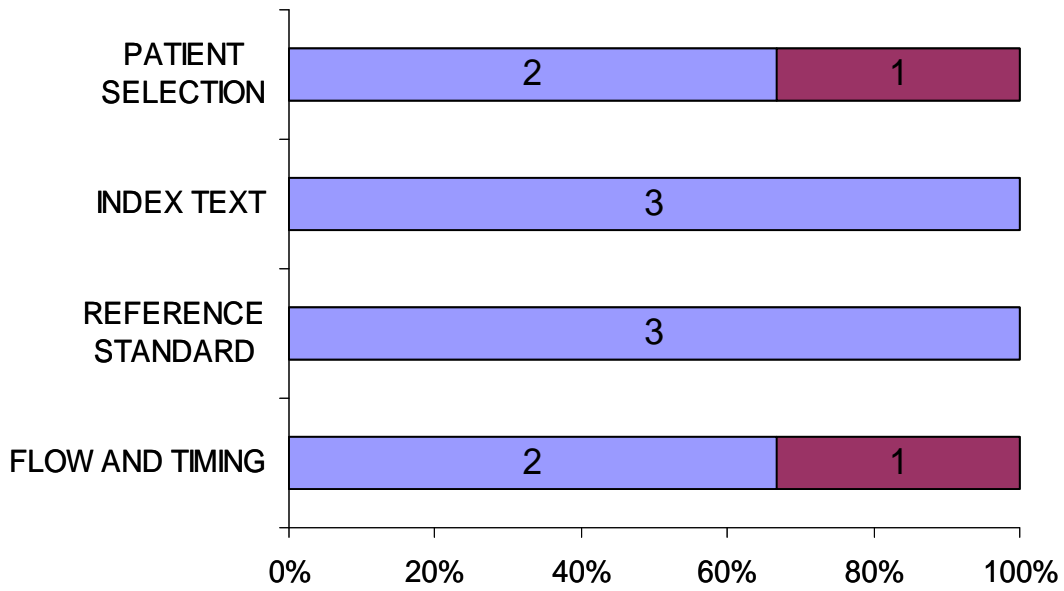
Applicability concerns



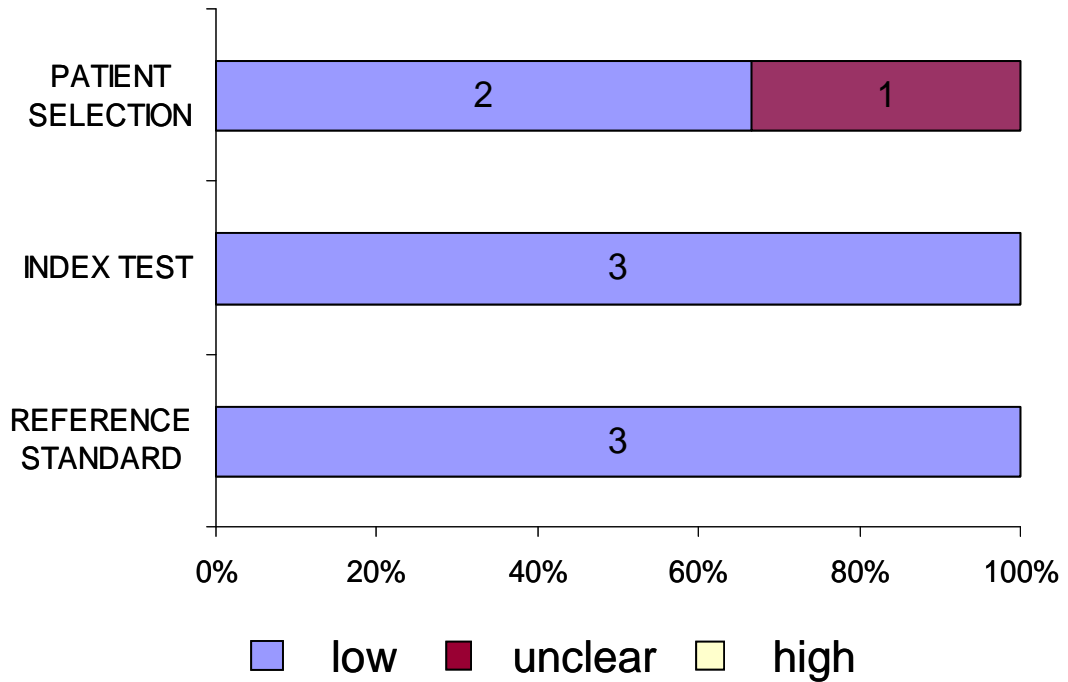
low    unclear    high

### R8

#### Risk of bias



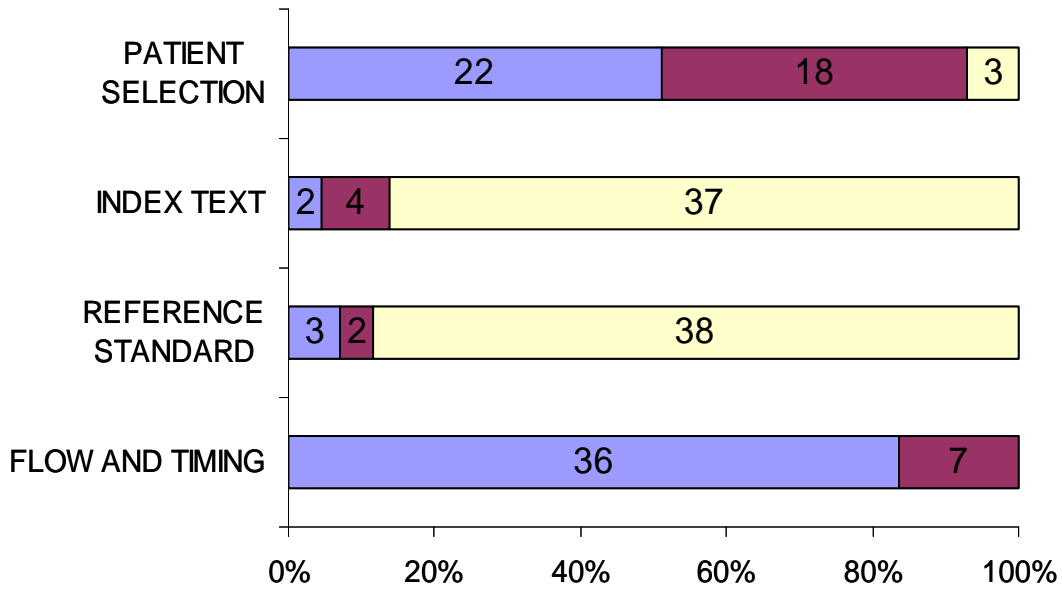
#### Applicability concerns



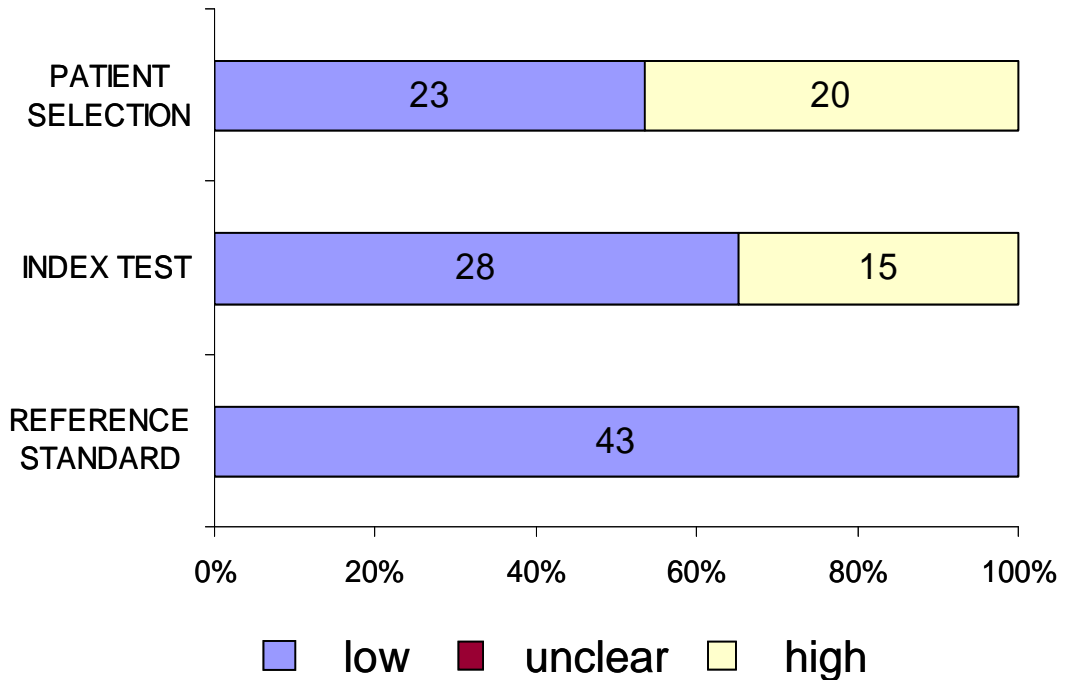


R10

Risk of bias



Applicability concerns



## EULAR recommendations for the use of imaging in spondyloarthritis

Imaging techniques are a key component of the classification of spondyloarthritis, allowing patients to be classified into distinct groups and to receive the appropriate treatment.

### INTRODUCTION

Spondyloarthritis is an umbrella term for several conditions that share many of the same features and symptoms, including ankylosing spondylitis, psoriatic arthritis and reactive arthritis. Patients can also be classified as having axial or non-axial (peripheral) disease, according to which joints in their body are affected. Axial disease affects the sacroiliac joint (in the back part of the pelvis) causing back pain and stiffness. It can be difficult to diagnose and classify these different diseases as they can lack distinguishing symptoms, and may develop over a long period of time. Therefore, imaging techniques that allow doctors to see inside the joints can be useful. These techniques include X-ray, magnetic resonance imaging (MRI), computerised tomography (CT scan) and ultrasound.

### WHAT DID THE AUTHORS HOPE TO FIND?

The authors hoped to gain a better understanding of the available literature and evidence supporting the use of various imaging techniques in spondyloarthritis in order to develop and publish recommendations for imaging in spondyloarthritis. The recommendations are intended to provide advice to doctors and patients, and to act as a measure of quality for treatment and management.

### WHO WAS STUDIED?

The recommendations are based on data from patients diagnosed with either established or suspected axial or peripheral spondyloarthritis and patients with chronic, non-inflammatory back pain as well as those with other rheumatic diseases and healthy control subjects. All patients were over the age of 18.

### HOW WAS THE STUDY CONDUCTED?

The basis of the recommendations was a systematic review, which aims to identify all the published evidence on a particular topic and draw it together into one summary. In this case a group of experts in spondyloarthritis, including both rheumatologists and radiologists, performed a systematic review on the role of imaging in diagnosis and monitoring, as well as its usefulness in predicting disease progression in spondyloarthritis. A total of 7550 references were identified, of which 158 were included in the final review. Based on the extracted evidence the experts drafted 10 recommendations for doctors to use.

### WHAT WERE THE MAIN FINDINGS OF THE STUDY?

The authors developed 10 recommendations for the use of imaging in patients with spondyloarthritis.

1. *Axial spondyloarthritis: diagnosis*
  - ▶ Conventional radiography (X-ray) of the sacroiliac joints in the lower back is recommended as the first imaging method. In young patients and those who have not had their symptoms for long, MRI may be used instead, although MRI of the spine is not generally recommended for this.
2. *Peripheral spondyloarthritis: diagnosis*
  - ▶ Ultrasound or MRI may be used to detect symptoms of peripheral spondyloarthritis.
3. *Axial spondyloarthritis: monitoring activity*
  - ▶ MRI of the sacroiliac joints and/or spine may be used to assess and monitor disease activity. The regularity of MRI depends on the clinical circumstances for each patient.
4. *Axial spondyloarthritis: monitoring structural changes*
  - ▶ Conventional radiography of the sacroiliac joints and/or spine may be used to monitor structural damage and new bone formation. It should not be repeated more often than every 2 years, and MRI can be used in between if more information is needed.
5. *Peripheral spondyloarthritis: monitoring activity*
  - ▶ Ultrasound and MRI may be used to monitor disease activity, and certain types of ultrasound can also detect inflammation. How often this should be performed depends on each patient's clinical circumstances.
6. *Peripheral spondyloarthritis: monitoring structural changes*
  - ▶ Conventional radiography is recommended, although MRI and/or ultrasound might provide additional information.

7. *Axial spondyloarthritis: predicting outcome/severity*
  - ▶ In patients with ankylosing spondylitis (not non-radiographic axial spondylitis), initial conventional radiography of the lumbar and cervical spine is recommended; MRI may also be used.
8. *Axial spondyloarthritis: predicting treatment effect*
  - ▶ Extensive MRI inflammatory activity in the spine of patients with ankylosing spondylitis might be used as a predictor of good clinical response to certain treatments.
9. *Spinal fracture*
  - ▶ When spinal fracture in axial spondylitis is suspected, conventional radiography is the recommended initial imaging method. If conventional radiography is negative, a CT scan should be performed. MRI is an additional imaging method which can also provide information on soft tissue lesions.
10. *Osteoporosis*
  - ▶ Osteoporosis should be assessed in some patients with axial spondylitis by bone density scanning.

### ARE THESE FINDINGS NEW?

Yes – these are the first recommendations from the European League Against Rheumatism (EULAR) that look at the entire spectrum of spondyloarthritis disease types and evaluate the role of all commonly used imaging techniques.

### HOW RELIABLE ARE THE FINDINGS?

The authors are confident that the findings are reliable and that the recommendations can be used by doctors with their patients.

For certain research questions that the authors asked – such as those dealing with predicting disease or treatment response – the review revealed only very few studies, and thus the recommendations in this area are based more on expert opinion than is the case with other areas where more study information and data were available.

### WHAT DO THE AUTHORS PLAN ON DOING WITH THIS INFORMATION?

The authors plan to make the recommendations available to both doctors and patients. It is EULAR policy to review and revise recommendations on a regular basis, so the process will be performed again to check for new data in 5 years.

### WHAT DOES THIS MEAN FOR ME?

These recommendations provide important information about the use of imaging techniques, both in diagnosis and management, and in predicting how patients will respond to treatments, as well as monitoring how their disease may be progressing at a structural level, before any symptoms occur.

The information in these recommendations may enable you to influence how your disease is diagnosed by being aware of what imaging techniques are useful. Being aware of how imaging techniques are used may also help you to understand why it is important to attend regular monitoring appointments, even if you feel well. If you have any questions about imaging, you should talk to your doctor.

**Disclaimer:** This is a summary of a scientific article written by a medical professional (“the Original Article”). The Summary is written to assist non medically trained readers to understand general points of the Original Article. It should not be relied on in any way whatsoever, (which also means the Summary is not medical advice), and is simply supplied to aid a lay understanding of general points of the Original Article. It is supplied “as is” without any warranty. You should note that the Original Article (and Summary) may not be accurate as errors can occur and also may be out of date as medical science is constantly changing. **It is very important that readers not rely on the content in the Summary and consult their medical professionals for all aspects of their health care. Do not use this Summary as medical advice even if the Summary is supplied to the reader by a medical professional.** Please view our full [Website Terms and Conditions](#).

Date summary prepared: July 2015

Summary based on research article published on: 2nd April 2015

From: Mandl, P. *et al.* EULAR recommendations for the use of imaging in the diagnosis and management of spondyloarthritis in clinical practice. *Ann Rheum Dis* 2015;74:1327–1339. doi:10.1136/annrheumdis-2014-206971LaySummary

Copyright © 2015 BMJ Publishing Group Ltd & European League Against Rheumatism. Medical professionals may print copies for their and their patients and students non commercial use. Other individuals may print a single copy for their personal, non commercial use. For other uses please contact our [Rights and Licensing Team](#).